

Content available at: <https://www.ipinnovative.com/open-access-journals>

IP Journal of Diagnostic Pathology and Oncology

Journal homepage: <https://www.jdpo.org/>

## Short Communication

# Re-defining oral squamous cell carcinoma

Tabita Joy Chettiankandy<sup>1</sup>, Arush Thakur<sup>2</sup>, Shubhangi P Khandekar<sup>3</sup>, Alka Dive<sup>3</sup>, Jagdish Vishnu Tupkari<sup>1</sup>, Sanpreet Singh Sachdev<sup>1,\*</sup>

<sup>1</sup>Dept. of Oral Pathology, Government Dental College and Hospital, Mumbai, Maharashtra, India

<sup>2</sup>Community Health Centre, Baroh, Kangra, Himachal Pradesh, India

<sup>3</sup>Dept. of Oral Pathology and Microbiology, VSPM's Dental College & Research Center, Nagpur, Maharashtra, India



### ARTICLE INFO

#### Article history:

Received 25-04-2022

Accepted 27-04-2022

Available online 19-05-2022

#### Keywords:

Oral Cancer

Definition

Neoplasm

Carcinogenesis

### ABSTRACT

Neoplasms of diverse cellular origin usually arise in the oral cavity and among these, the oral squamous cell carcinoma (OSCC) and its variants constitute over 90% of the oral malignancies. India is a global hub of OSCC cases. Throughout the changing trends and rise of different generations various authors have tried to define oral cancer. However, there is no definition that describes it in depth for a better understanding. But none of the definition define OSCC in a nutshell. Therefore, the need of the hour is to elaborately define OSCC. The present paper attempts to propose a new definition for OSCC that comprehensively encompasses the etiological, molecular, biological, histopathological and prognostic aspects of OSCC.

This is an Open Access (OA) journal, and articles are distributed under the terms of the [Creative Commons Attribution-NonCommercial-ShareAlike 4.0 License](https://creativecommons.org/licenses/by-nc-sa/4.0/), which allows others to remix, tweak, and build upon the work non-commercially, as long as appropriate credit is given and the new creations are licensed under the identical terms.

For reprints contact: [reprint@ipinnovative.com](mailto:reprint@ipinnovative.com)

## 1. Introduction

When one is to define a medical entity, the definition must clarify every aspect of the disease including its etiopathogenesis, biological behavior and characteristic features. Definitions ensure a common interpretation of a disease, consequently minimizing discrepancies in diagnosis.<sup>1</sup> An ambiguous definition would lead to incomplete or even misinterpretation, only serving to create confusion.

The most common oral cancer, comprising 90% of the cases i.e Oral Squamous cell carcinoma was defined as 'a malignant epithelial neoplasm exhibiting squamous differentiation as characterized by the formation of keratin and/or the presence of intercellular bridges' by Pindborg.<sup>2</sup> While the definition expresses the essence of pathogenesis of OSCC, it fails to comprehensively cover various other aspects of the disease. The histopathological features

described in the existing definition may be shared by other lesions exhibiting squamous metaplasia.<sup>3</sup>

Despite constituting the major cancer burden globally, there has been no update with respect to the definition of OSCC. Over the years, researchers have identified numerous complex interactions occurring in the tumor microenvironment (TME) during the development of OSCC.<sup>4</sup> A definition that precisely describes OSCC with respect to its etiopathology, biological behavior, molecular changes, and progression is long overdue.

In this context, we have attempted to re-define OSCC with an objective to clarify almost every aspect of the disease for the readers.

## 2. Proposed Definition of OSCC

“Oral squamous cell carcinoma can be defined as an epithelial malignancy involving any part of the oral mucosa caused by multiple persistent, accumulated stepwise changes in gene expression on account of

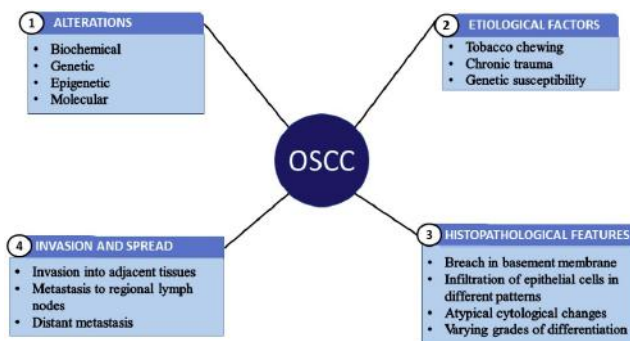
\* Corresponding author.

E-mail address: [sunpreets@yahoo.in](mailto:sunpreets@yahoo.in) (S. S. Sachdev).

biochemical, genetic, epigenetic, and molecular alterations \ mutations both within the squamous cell epithelium and within the stroma, as a result of continuous exposure to biological, physical, chemical carcinogens predominantly tobacco products or from chronic trauma from tooth/ dental prosthesis or appliances, and/or genetic susceptibility, leading to dysregulated, uncoordinated, uncontrolled proliferation of epithelial cells, eventually evolving into a population of dysplastic epithelial cells that breach the basement membrane, infiltrate the connective tissue in the form of epithelial islands, strands or keratin pearls or individual atypical cells portraying different grades of differentiation from well to poorly differentiated which further invade the adjacent tissues, metastasize to the regional lymph nodes and distant sites primarily through lymphatics resulting in significant morbidity and mortality if not diagnosed or left untreated.”

### 3. Discussion

Most of the previous definitions have included only morphological changes occurring in the epithelium. The proposed definition comprehensively encompasses the etiological factors, pathogenesis, histological grades, metastases and biological behavior of OSCC [Figure 1].



**Fig. 1:** Aspects of OSCC encompassed in the proposed definition

The initial part of the definition focuses on the genetic alterations that take place within the TME, which accumulate over a long period of time.<sup>5</sup> During the past decades, focus of cancer research has shifted from the malignant cancer cells to the TME and its complex molecular interactions.<sup>4</sup> The molecular alterations occurring in the TME include methylation/silencing of tumor suppressor genes and evasive ability against immune response leading to uncontrolled proliferation of the cells, loss of cell adhesion molecules between the cells imparting them with increased migratory activity and degeneration of extracellular matrix allowing the tumor cells to infiltrate into the stroma.<sup>6</sup> Therefore, OSCC is not merely a malignant proliferation of squamous cells but involves numerous molecular, genetic and epigenetic alterations in the stromal part of TME.

The second part focuses on the etiological factors inciting these biomolecular alterations. A sharp increase in oral cancer cases specifically in the younger individuals has been noted in India.<sup>7</sup> This could be related to lifestyle habit of tobacco chewing and its association to oral cancer which has also led to the aphorism ‘Cancer is where tobacco is’. Recent literature review also revealed that chronic mucosal irritation resulting from dentures, broken teeth, sharp teeth and overhanging restorations may be considered a risk for development of oral cancer.<sup>8</sup>

The subsequent part of the definition covers the most important aspect of OSCC, which is the spectrum of its histopathological features. Breach of basement membrane and invasion of neoplastic epithelial cells, together constitute the hallmark of OSCC. The invasion of epithelial cells into the stroma may proceed in a myriad of infiltrative patterns. Additionally, the cells may show varied degrees of differentiation from squamous cells highly differentiated to the point of keratin pearl formation, to poorly differentiated cells that closely resemble mesenchymal phenotype.<sup>2,5</sup>

The definition then describes the most dreadful aspect of the disease, which is local and distant metastases. Metastases may initially occur in the tissues adjacent to primary focus or origin. Carcinogenetic changes may also initiate in other sites in the oral cavity owing to field cancerization.<sup>9</sup> The spread may then extend to the lymph nodes draining the site. Therefore, the definition hints at the importance of lymph node assessment linking to the oral structures that they drain.

The significance of classifying and defining any entity lies on its clinical implications. It has been demonstrated that diagnosis and treatment of OSCC at advanced stages has a 5-year survival rate of only 20% as compared to those at early stages (80%).<sup>10</sup> Therefore, the definition lastly emphasizes on the importance of timely diagnosis and treatment of the disease, failure of which would have dreadful outcomes, given the aggressive biological nature of the tumor.

### 4. Conclusion

With increase in the understanding of various aspects of OSCC, updating its existing definition was long overdue. The present attempt to redefine it in a nutshell aimed to bring the exact meaning and understanding of the global malice. Just like the molecular alterations in OSCC, the definitions of OSCC such as ours, may also undergo cumulative alterations until a perfect one is tailored.

### 5. Conflict of Interest

The authors declare no relevant conflicts of interest.

### 6. Source of Funding

None.

## References

1. Doust J, Vandvik PO, Qaseem A, Mustafa RA, Horvath AR, Frances A, et al. Guidance for modifying the definition of diseases: a checklist. *JAMA Int Med.* 2017;177(7):1020–5.
2. Pindborg JJ, Reichart PA, Smith CJ. Histological typing of Cancer and Precancer of the Oral Mucosa. 1st Edn. New York: Springer; 1971.
3. Moscicki AB, Burt VG, Kanowitz S, Darragh T, and SS. The significance of squamous metaplasia in the development of low grade squamous intraepithelial lesions in young women. *Cancer.* 1999;85(5):1139–44.
4. Boxberg M, Leising L, Steiger K, Jesinghaus M, Alkhamas A, Mielke M, et al. Composition and clinical impact of the immunologic tumor microenvironment in oral squamous cell carcinoma. *J Immunol.* 2019;202(1):278–91.
5. Rivera C, Venegas B. Histological and molecular aspects of oral squamous cell carcinoma. *Oncol Letters.* 2014;8(1):7–11.
6. Das D, Ghosh S, Maitra A, Biswas NK, Panda CK, Roy B, et al. Epigenomic dysregulation-mediated alterations of key biological pathways and tumor immune evasion are hallmarks of gingivo-buccal oral cancer. *Clin Epigenetics.* 2019;11(1):1–2.
7. Abdulla R, Adyanthaya S, Kini P, Mohanty V, D'Souza N, Subbannayya Y, et al. Clinicopathological analysis of oral squamous cell carcinoma among the younger age group in coastal Karnataka, India: A retrospective study. *J Oral Maxillofac Pathol.* 2018;22(2):180–7. doi:10.4103/jomfp.JOMFP\_16\_18.
8. Gupta AA, Kheur S, Varadarajan S, Parveen S, Dewan H, Alhazmi YA, et al. Chronic mechanical irritation and oral squamous cell carcinoma: A systematic review and meta-analysis. *Bosnian J Basic Med Sci.* 2021;21(6):647–58.
9. Simple M, Suresh A, Das D, Kuriakose MA. Cancer stem cells and field cancerization of oral squamous cell carcinoma. *Oral Oncol.* 2015;51(7):643–51.
10. Ries LA, Melbert D, Krapcho M, Stinchcomb DG, Howlander N, Horner MJ, et al. SEER cancer statistics review. Bethesda, MD: National Cancer Institute; 1975.

## Author biography


**Tabita Joy Chettiankandy**, Professor (Acad) and HOD

**Arush Thakur**, Medical Officer (Dental)

**Shubhangi P Khandekar**, Professor and Ph.D Guide

**Alka Dive**, Professor, HOD and Ph.D Guide

**Jagdish Vishnu Tupkari**, Hon. Professor and Ph.D Guide

**Sanpreet Singh Sachdev**, Post Graduate  <https://orcid.org/0000-0001-7655-8180>

**Cite this article:** Chettiankandy TJ, Thakur A, Khandekar SP, Dive A, Tupkari JV, Sachdev SS. Re-defining oral squamous cell carcinoma. *IP J Diagn Pathol Oncol* 2022;7(2):145-147.