

Guide Flange Prosthesis

Pratiksha Shetty¹, Arti Gangurde², Jyoti Tembhurne³

¹Post Graduate Student, Government Dental College & Hospital, Mumbai

²Associate Professor, Government Dental College & Hospital, Mumbai

³Professor & Head, Government Dental College & Hospital, Mumbai

Abstract:

This article introduces the concept of guide flange prosthesis as a rehabilitative solution for patients undergoing hemi-mandibulectomy due to oral squamous cell carcinoma (OSCC). OSCC is a prevalent malignancy, particularly in India, necessitating surgical resection that often leads to functional impairments and aesthetic challenges. Mandibular continuity loss results in issues like mandibular deviation, occlusal plane rotation, and cosmetic disfigurement.

The guide flange prosthesis, discussed through a case report of a 45-year-old male post-hemi-mandibulectomy, aims to stabilize the remaining mandibular segment, reduce deviation, and enhance chewing function. The article emphasizes the importance of comprehensive rehabilitation, especially when dental implants may be contra-indicated due to radiotherapy. The case involves the fabrication process of the prosthesis using perforated partial impression trays, irreversible hydrocolloid, and a stainless steel orthodontic wire substructure.

The patient's successful adaptation to the guide flange prosthesis, providing stability and improved mastication, highlights its significance in the post-resection phase. The article also discusses the prevalence of oral cancers in India, surgical interventions, and the role of innovative approaches like guide flange prostheses in addressing the challenges of oral cancer reconstruction. Overall, the integration of surgical techniques and prosthetic interventions offers hope for enhanced outcomes in the complex landscape of oral cancer rehabilitation.

Introduction:

Oral squamous cell carcinoma (OSCC) represents a prevalent malignancy within the oral cavity and stands as the 12th most frequently diagnosed cancer worldwide.¹ In the context of India, it emerges as one of the top three common malignant neoplasms.² OSCC predominantly manifests along the lateral aspects of the tongue and the floor of the oral cavity, carrying a substantial risk of infiltration into the mandible. Consequently, comprehensive management entails surgical resection encompassing extensive segments of the tongue, floor of the mouth, and regional lymphatic structures. Thus, addressing this condition presents a formidable challenge for healthcare professionals, as it necessitates a dual focus on disease control and post-treatment rehabilitation.^{3,4} Loss of mandibular continuity can engender profound functional impairments, affecting mastication, speech articulation, and the swallowing process. Notable consequences encompass mandibular deviation towards the afflicted side during functional movements, an inferior rotation of the occlusal plane, excessive salivary drooling, and severe cosmetic disfigurement.⁵ Dental implants have been proposed as an alternative to rehabilitate patients after

partial mandibulectomy because they may improve prostheses retention, stability and oral function.⁶ However, the majority of patients submitted to surgical resections as a consequence of orofacial tumors are treated with radiotherapy to diminish the probability of metastasis, and this treatment may be contraindicated for dental implants. Patients who underwent radiotherapy treatment are associated to low survival rates of dental implants.⁷ Removable partial dentures for hemimandibulectomy patients must be custom-designed to accommodate the unique anatomy of the individual. The denture should compensate for the missing portion of the mandible while providing adequate support and stability. Utilizing clasps, attachments, or other retention mechanisms on the remaining natural teeth can enhance stability. In cases where significant bone and tissue loss has occurred, custom maxillofacial prostheses can be created to restore the missing structures and provide a more balanced facial appearance.⁸ A guide flange prosthesis is a removable dental prosthesis designed to stabilize the remaining mandibular segment and reduce mandibular deviation. By stabilizing the mandible, these prostheses assist in regaining chewing function. They provide a more stable platform for mastication, allowing patients to consume a more varied diet and improve their overall nutritional intake.^{9,10}

Case Report: A 45 year old male reported to the Department of Prosthodontics and Crown & Bridge, Government Dental College & Hospital, Mumbai, for prosthetic rehabilitation following hemimandibulectomy 3 years back (Fig 1,2). A detailed case history revealed that the patient was diagnosed with squamous cell carcinoma of the left buccal mucosa due to which partial maxillectomy and hemimandibulectomy had to be carried out. A Pectoralis Major Myocutaneous (PMMC) flap was used to rehabilitate the soft tissue surgical defect. As no hard tissue reconstruction was undertaken, prosthetic rehabilitation in the resected region was compromised. Eventually, scar tissue formation and contracture occurred in the left buccal mucosa region which limited the mouth opening to 10-12 mm. Deviation of the mandible was noted to the left side. The patient was able to guide the mandible into occlusion to the right side but was unable to maintain this position due to resection of the left condyle. Tooth number 45 (FDI notation) was missing. The patient was classified as Class IV (severely compromised) according to Prosthodontic Diagnostic Index Resources for partial edentulous patients as described by McGarry et al. and Class III (resection defect involves loss upto the mandibular midline region) according to Cantor and Curtis classification of mandibular defects.

Perforated partial impression trays and irreversible hydrocolloid (Dentsply Zelgan Advanced Alginate) were used to make primary impressions of the maxillary and mandibular arch. The impressions were poured in Type III gypsum material (Kalstone; Kalabhai Karson, Mumbai, India) and casts were retrieved. A wax bite was obtained by guiding the mandible into the correct position. The maxillary and mandibular casts were stabilised using matchsticks and sticky wax and mounted on a mean value articulator (Fig 3). A 19 gauge round stainless steel orthodontic wire was manipulated (Fig 4) to fabricate a substructure for the guide flange prosthesis. The wire substructure was modified into 2 components to accommodate the replacement of the missing tooth in the 4th quadrant. A C clasp engaged the mandibular right 1st premolar and a separate buccal wire component was adapted such that it passed between the occlusal surfaces of the mandibular right 1st and 2nd molar. The guide flange was waxed up on the buccal and lingual side with modelling wax (Chromawax, Chromadent Dental Equipments, Mumbai, India) around the wire substructure (Fig 5). A putty index (Fig 6) of the waxed up guide flange was made using condensation silicone (Zhermack Zetaplus Elastomeric Impression Material) and sectioned into buccal and lingual

halves. Modelling wax was removed and clear autopolymerizing resin (DPI Cold Cure, Dental Products of India, Mumbai, India) was used to fabricate the prosthesis. The lingual half was acrylicised first followed by the buccal half(Fig 7). The guide flange prosthesis was finished and polished in usual manner(Fig 8). The guide flange prosthesis was tried in the patient's mouth and retention and stability were checked. The inclination of the guide flange was adjusted by selective trimming of the surface in contact with the buccal surfaces of the maxillary teeth. Care was taken to preserve the indentations of the maxillary teeth which were guiding the mandible in a final definite closing point during mastication. The flange height was adjusted to enable smooth unhindered motion of the mandible from maximum mouth opening to maximum intercuspation. The prosthesis was delivered and post-insertion instructions were given. The patient was followed up at 1 week and was kept on a regular follow up of 1 month for 1 year. The patient was pleased with the overall performance of the prosthesis and successfully speaks and masticates without clinically significant deviation

Discussion:

India has the highest global incidence of oral cancers, affecting nearly 20% of the population. Surgical interventions for mandibular tumors include various modalities such as marginal, segmental, hemi, subtotal, or total mandibulectomy. Loss of mandibular integrity causes displacement and rotation of mandibular segments, impacting occlusal plane alignment.

Reconstruction using a PMMC flap, a versatile and reliable technique developed in 1979 by Ariyan, addresses this challenge.^{13,14} The flap, extending from the buccal aspect of a mandibular prosthesis, connects with opposing maxillary teeth, ensuring proper mediolateral positioning for vertical chewing with limited lateral movement.

Post-mandibular resection, prompt reconstruction is crucial for facial symmetry and masticatory function restoration. Despite advances in surgery and prosthodontic rehabilitation, many head and neck cancer patients report mastication issues after reconstruction.

Recent innovations like dental implants offer promise for oral cancer patient rehabilitation, enabling a return to a healthier life.¹⁵ However, implant acceptance requires a lengthy healing period, often exceeding a year. Early prosthodontic intervention during this period, involving a mandibular guide flange, minimizes mandibular deviation and enhances masticatory efficiency. The lingual flange stabilizes the prosthesis. Support for the guide flange prosthesis relies on natural teeth and the remaining alveolar ridge. Placement of retentive clasps, adjusted based on tooth positions, is crucial, for prosthesis retention and stability in function.

Conclusion:

The guide flange prosthesis functions as a training-type prosthesis, and successful maintenance of mediolateral position may allow discontinuation. Some patients, however, may continue using it indefinitely, requiring careful monitoring of stress on remaining teeth. Overall, the integration of surgical techniques, prosthetic interventions, and innovative approaches offers hope for improved outcomes in the challenging landscape of oral cancer reconstruction.

References:

1. Misra S, Chaturvedi A, Misra NC. Management of gingivobuccal complex cancer. *Ann R Coll Surg Engl.* 2008;90:546–53.
2. Abdulla R, Adyanthaya S, Kini P, Mohanty V, D’Souza N, Subbannayya Y, et al. Clinicopathological analysis of oral squamous cell carcinoma among the younger age group in coastal Karnataka, India: A retrospective study. *J Oral Maxillofac Pathol.* 2018;22:180–7.
3. Taylor TD. Diagnostic considerations for prosthodontic rehabilitation of the mandibulectomy patient. In: Taylor TD, editor. *Clinical maxillofacial prosthetics.* Chicago: Quintessence Publishing; 2000. pp. 155–70.
4. Olson ML, Shedd DP. Disability and rehabilitation in head and neck cancer patients after treatment. *Head Neck Surg.* 1978;1:52–8.
5. Beumer J, III, Marunick M, Esposito S. *Maxillofacial Rehabilitation: Prosthodontic and Surgical Management of Cancer-Related, Acquired, and Congenital Defects of the Head and Neck.* 3rd ed. New Delhi, India: Quintessence; 2011.
6. Carini F, Gatti G, Saggese V, Monai D, Porcaro G. Implant-supported denture rehabilitation on a hemimandibulectomized patient: a case report. *Ann Stomatol (Roma).* 2012;3(2 Suppl):26-31.
7. MacInnes A, Lamont T. Radiotherapy associated with higher rates of dental implant loss. *Evid Based Dent.* 2014;15(1):27-8.
8. Carlsson GE, Hedegård B. Changes in the masticatory system after insertion of removable partial dentures. *J Prosthet Dent.* 1965;15(2):246-56.
9. Dholam KP, Somkumar K, Shete P, et al. Prosthetic rehabilitation of hemimandibulectomy patient: A clinical report. *J Indian Prosthodont Soc.* 2015;15(4):397-401.
10. Beumer J, Curtis TA, Firtell DN. *Maxillofacial Rehabilitation: Prosthodontic and Surgical Management of Cancer-Related, Acquired, and Congenital Defects of the Head and Neck.* Quintessence Publishing Company; 1996.
11. Patil PG, Patil SP. Guide flange prosthesis for early management of reconstructed hemimandibulectomy: a case report. *J Adv Prosthodont.* 2011;3(3):172-6.
12. Bandodkar S, Arya D, Singh SV, Chand P. Guide flange Prosthesis for management of hemimandibulectomy. *Natl J Maxillofac Surg.* 2021;12(2):289-93.
13. Chaturvedi P. Effective strategies for oral cancer control in India. *J Cancer Res Ther.* 2012;8(Suppl 1):S55–6.
14. Tripathi M, Parshad S, Karwasra RK, Singh V. Pectoralis major myocutaneous flap in head and neck reconstruction: An experience in 100 consecutive cases. *Natl J Maxillofac Surg.* 2015;6(1):37-41.
15. Taylor TD, editor. *Clinical Maxillofacial Prosthetics.* Chicago: Quintessence Publishing; 2000. Diagnostic considerations for prosthodontic rehabilitation of the mandibulectomy patient; pp. 155–170.

Fig 1: Extraoral view (frontal)

Fig 2: Intraoral view (frontal)

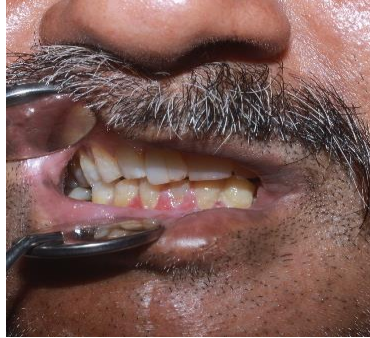

Fig 3: Mounting of maxillary and mandibular casts on mean value articulator

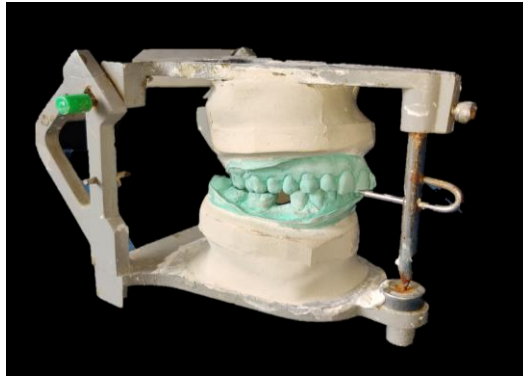


Fig 4: Wire substructure modified to accommodate missing tooth. C clasp on tooth number 45 (FDI notation)- Occlusal view

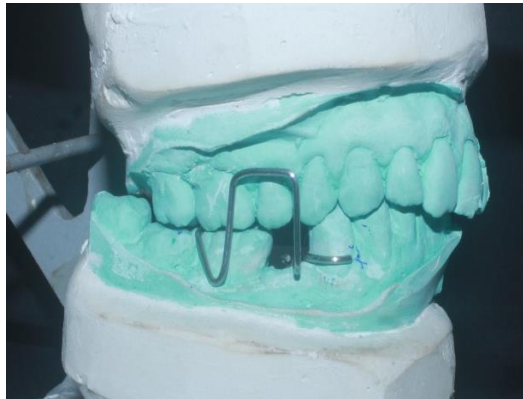

Fig 5: Adaptation of wax over wire substructure- Occlusal view

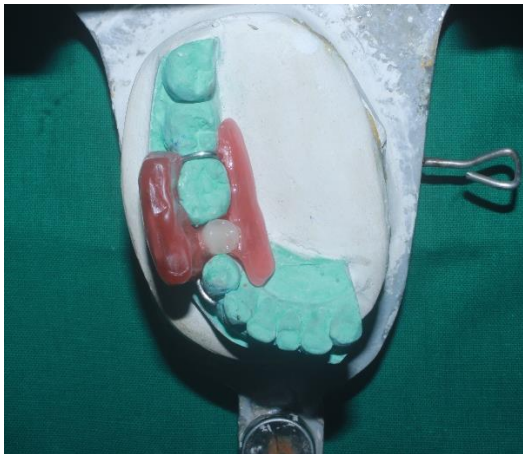

Fig 6: Putty index made of the waxed up guide flange prosthesis

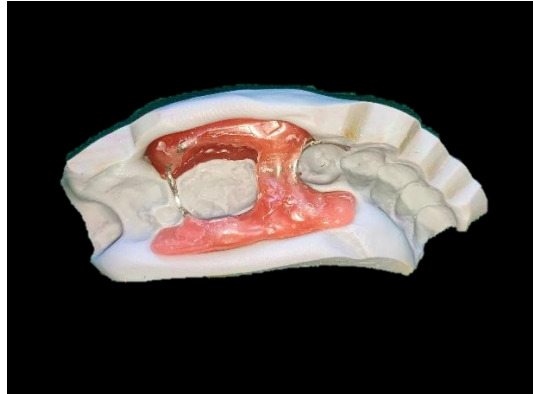


Fig 7: Acrylization of lingual half of the prosthesis using the sectioned putty index



Fig 8: Prosthesis insertion in patient's mouth

