

Content available at: <https://www.ipinnovative.com/open-access-journals>

IP International Journal of Maxillofacial Imaging

Journal homepage: <https://www.ijmi.in/>

Case Report

Mesiodens - Obvious yet unnoticed: A case report

Sanpreet Singh Sachdev^{1,*}, Yogita Adhane¹, Tabita Joy Chettiankandy¹,
Manisha Ahire Sardar¹, Ashwini Chhapane²

¹Dept. of Oral Pathology and Microbiology, Government Dental College and Hospital, Mumbai, Maharashtra, India

²Dept. of Oral and Maxillofacial Surgery, Government Dental College and Hospital, Mumbai, Maharashtra, India



ARTICLE INFO

Article history:

Received 19-11-2022

Accepted 04-12-2022

Available online 28-12-2022

Keywords:

Developmental anomaly
Cone beam computed tomography
Mesiodens

ABSTRACT

Supernumerary teeth occurring in between the central incisors are termed ‘mesiodens’ and have a prevalence rate of 3% in the Asian population. Mesiodens is seldom observed in adults with permanent dentition as most of them get extracted within the first decade or early second decade. The present case report describes mesiodens in a 32-year-old male with an emphasis on its radiological and histological aspects. Although a fairly common dental anomaly, mesiodens may present with several complications and have clinical implications in treatment. Retention of mesiodens until the fourth decade is quite unusual and is, therefore, an interesting aspect of the present case.

This is an Open Access (OA) journal, and articles are distributed under the terms of the [Creative Commons Attribution-NonCommercial-ShareAlike 4.0 License](https://creativecommons.org/licenses/by-nc-sa/4.0/), which allows others to remix, tweak, and build upon the work non-commercially, as long as appropriate credit is given and the new creations are licensed under the identical terms.

For reprints contact: reprint@ipinnovative.com

1. Introduction

Supernumerary teeth are those that are not a part of and are present in addition to the general set of teeth. Thus, in patients with supernumerary teeth, the total number of teeth present in the mouth exceeds that of normal dentition. The prevalence of supernumerary teeth has been described as being in the range of 0.09 to 3.9% of individuals.¹ There is a strong propensity for supernumerary teeth to occur in the premaxillary area.² 90% of these occur in between the maxillary central incisors and are termed ‘mesiodens’.

The prevalence of mesiodens is higher in the Asian population, being present in about 3% of individuals.^{3,4} It is usually found in primary dentition, wherein it may impede the eruption of adjacent central incisors, cause crowding, or be associated with cystic lesions. Therefore, the anomaly gets noticed around 7 to 9 years, and most mesiodens are found during the mixed dentition period.⁵ Timely removal of mesiodens leads to a normal eruption of the central

incisors owing to the eruption path of lateral incisors and canine.

Mesiodens are seldom observed in adults with permanent dentition as most of them get extracted within the first decade or early second decade.⁶ Although the mesiodens may be asymptomatic for it to remain unnoticed until adulthood, it can pose several clinical problems, particularly in the aesthetics of the individual. While radiographs aid in the diagnosis of impacted mesiodens, those that erupt are seldom subjected to radiological or histological analysis. Most clinicians consider clinical examination and extraction as sufficient without delving much into the details of the anomaly.

The present case report describes mesiodens in a 32-year-old male with an emphasis on its radiological and histological aspects.

2. Case Report

A 32-year-old male complained of an unsightly tooth in the upper front region of the jaw for more than 15 years.

* Corresponding author.

E-mail address: sunpreets@yahoo.in (S. S. Sachdev).

The patient initially did not consider it much of an issue and therefore, did not have a history of a prior dental visit. The patient was presently concerned about how the tooth was affecting the aesthetics and therefore, reported to our institution to get it treated. The patient’s medical history was unremarkable. General examination revealed that all the vital parameters were within normal range. Extra-orally, no gross facial asymmetry or protrusion was noticeable.

On intra-oral examination, the patient exhibited a supernumerary tooth in between the central incisors (Figure 1). The tooth resembled incisors in its basic shape, except that it was smaller in dimensions. Its color was also identical to that of the adjacent teeth. The tooth was rotated distally with its lingual surface facing the permanent maxillary right central incisor. Mild buccal tipping of the tooth was also noted. The crown exhibited a deep groove running vertically across the middle third of this lingual surface. Mild stains, calculus, and gingival inflammation were noticeable across all the teeth and also including the supernumerary tooth. Stains were also evident in the lingual groove of the supernumerary tooth.

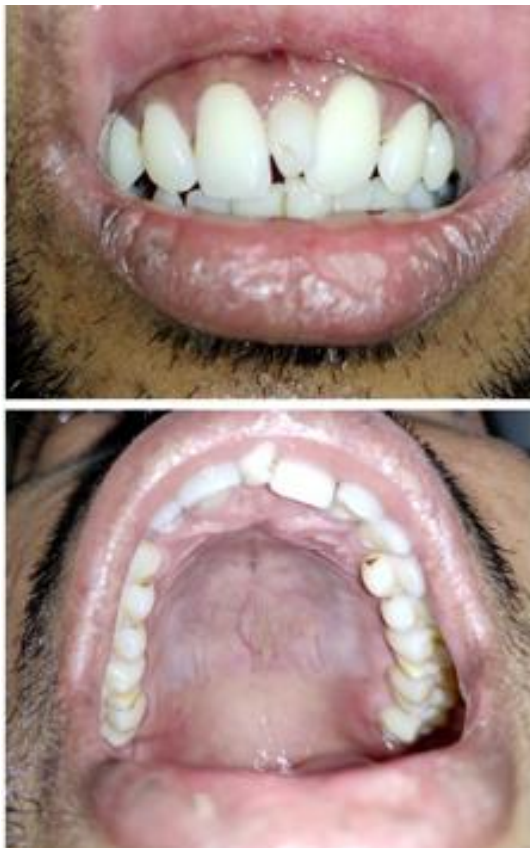

Fig. 1: Distally rotated mesiodens present in between the maxillary central incisors

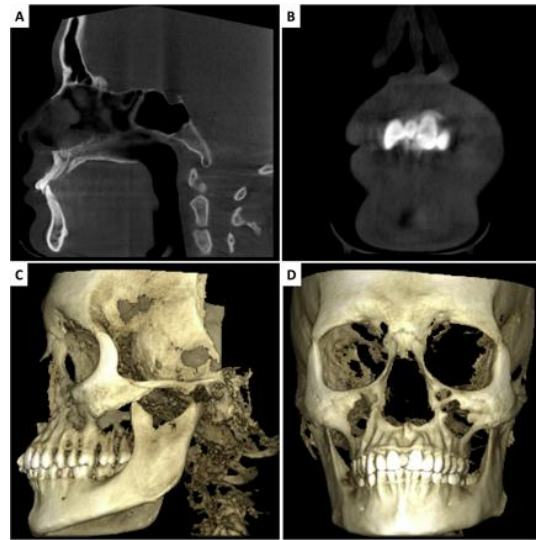


Fig. 2: CBCT exhibiting mesiodens in between the maxillary central incisors in A) Sagittal view, B) Coronal view, C) and D) 3-dimensional reconstruction models

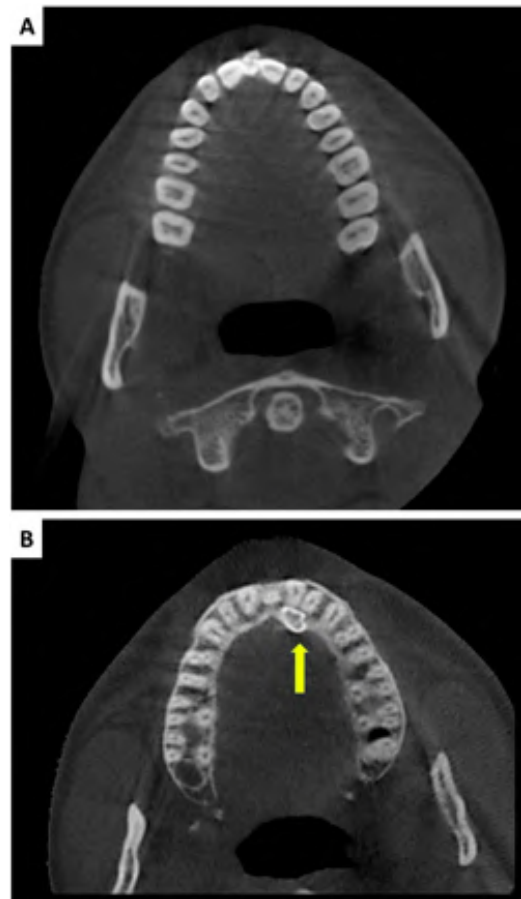


Fig. 3: CBCT in axial view exhibiting A) buccally tipped crown of the mesiodens and B) apex of the root of mesiodens on the lingual aspect of maxillary left central incisor

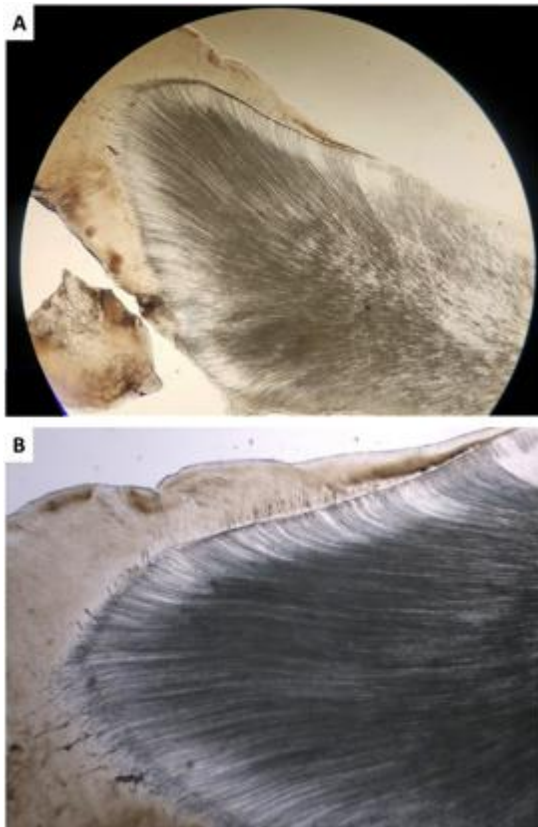


Fig. 4: Ground section of teeth showing A) Coronal and radicular portion of the mesiodens original magnification x40, and B) Bulk of dentin surrounded by enamel under original magnification x100

A cone-beam computed tomography (CBCT) scan revealed a tooth-like structure consisting of hyperdense enamel, less hyperdense dentin, and a radiolucent pulp chamber (Figure 2). The crown was 4.5 mm in height with a 4 mm mesiodistal width while the root was 3.5 mm long. The apex of its root was found to be lingual to the maxillary left central incisor (Figure 3). A clinical diagnosis of ‘mesiodens’ was imparted.

The treatment plan was decided as the extraction of the mesiodens followed by observation for at least six months. The longitudinal ground section of the extracted tooth consisted of coronal and radicular portions (Figure 4). The coronal portion consisted of a bulk of dentin surrounded by enamel with enamel rods, lamellae, and tufts. S-shaped dentinal tubules with scalloped dentin-enamel junction, as observed in normal tooth structure, were also evident. The radicular portion comprised similarly appearing dentinal tubules surrounded by a prominent tome’s granular layer at the cementodentinal junction.

3. Discussion

Nearly two-thirds of cases of mesiodens occur in males with a mean age of diagnosis being 6.35 ± 1.85 years.⁶ What

makes the present case interesting is its retention until the fourth decade without any associated symptoms. Shih et al. analyzed 105 cases of mesiodens and found that only one case had mesiodens in the permanent dentition while the majority of the cases were diagnosed within or before the early mixed dentition period (95.2%).⁶

Mesiodens most often have clinical implications such as delayed eruption, rotation or root resorption of adjacent teeth, malocclusion, and mid-line diastema. At times, they may be associated with cystic lesions or even erupt in the nasal cavity.⁷ Only less than 20% of cases of mesiodens are free of symptoms without any associated pathology. In the asymptomatic cases of mesiodens, the anomaly is usually diagnosed during routine clinical/radiographic examination.^{8,9} Yet, in the present case, the patient did not have any complaints or prior visits to a dental clinic; therefore, the tooth remained unnoticed.

While the exact mechanism of mesiodens formation is yet unclear, several theories have been proposed over the years. These include a combination of genetic and environmental factors, hyperactivity of dental lamina or its rests, dichotomy or palatal off-shoots from the tooth bud among the most accepted ones.^{10,11} Additionally, various syndromes such as Gardner’s syndrome, cleidocranial dysplasia, Oral-facial-digital syndrome, Rothmund-Thomson syndrome, and many others frequently consist of supernumerary teeth within their spectrum of disorders.¹² In the present case, the mesiodens was not associated with any symptoms nor were any other pathologies present elsewhere.

The mesiodens may be single, bilateral, or multiple; particularly in syndromic cases, multiple supernumerary teeth may be noted which is termed ‘mesiodentes’.¹³ It may assume various clinical forms such as conical or peg-shaped, tuberculate or barrel-shaped, and supplemental or tooth-like.¹² In the present case, a single peg-shaped mesiodens was noted which corroborated findings reported by Shih et al. that about 90% of mesiodens are conical or peg-shaped.⁶

An orthopantomogram is usually not advisable for visualizing the anterior parts of the jaws owing to frequent overlaps between adjacent structures. Furthermore, it is crucial to visualize the three-dimensional spatial orientation of the supernumerary tooth concerning the adjacent teeth of the normal series to precisely decide the treatment plan and predict its clinical outcome. A CBCT proves to be superior in this aspect providing accurate information about the spatial orientation, relation to the neighboring anatomic structures, local pathologies, or identifying risks of harming adjacent structures (such as adjacent tooth buds in mixed dentition).¹⁴

Unlike odontoma, wherein a disorganized mass of dental tissue-like structures is noted, a relatively well-organized tooth structure is usually present in

supernumerary teeth including mesiodens.¹² As observed in this histopathological picture of our case, the dentin and enamel were normally laid down with structures like enamel rods, lamellae, and tufts, scalloped dentin-enamel junction, and Tome's granular layer being evident.

Usually, the major concern in mesiodens occurs when it hinders the eruption of adjacent maxillary central incisors. Depending upon several factors such as the depth of impacted teeth, amount of root formed, angulation of the mesiodens and the impacted teeth, and many others. Immediate orthodontic traction is, thus, suggested in such cases to avoid a second surgery.¹⁵ However, since the present case occurred in an adult with well-developed and completely erupted dentition, consideration for orthodontic traction was not necessary.

Another reason for orthodontic treatment in patients with mesiodens is the rotation of the adjacent permanent incisors.⁶ This is generally caused by crowding that occurs due to an additional tooth occupying space in the arch perimeter reserved for teeth of the normal series without a compensatory increase in the jaw size. Omer et al. suggested that older patients with a more developed dentition usually exhibit more of these complications.¹⁶ However, besides the mesiodens itself being rotated, none of the other teeth exhibited signs of malocclusion except for the obvious crowding. Therefore, a wait-and-watch approach was adopted for the present case rather than immediately recommending orthodontic treatment to the patient.

Even after the extraction of mesiodens, close monitoring of the dentition is highly recommended along with radiographic assessment after 6 months.¹⁷ A more diligent follow-up is required to assess the rate of eruption in cases where the adjacent teeth are impacted due to mesiodens. In this case, however, since all the teeth of the general set were erupted, a follow-up after 6 months was advised for the patient.

4. Conclusion

Although a fairly common dental anomaly, mesiodens may present with several complications and have clinical implications in treatment. Retention of mesiodens until the fourth decade is quite unusual and is, therefore, an interesting aspect of the present case. Our case also highlights the importance of CBCT in the management of patients with mesiodens.

5. Source of Funding

None.


6. Conflict of Interest

None.


References


- Montenegro PF, Castellon EV, Aytes LB, Escoda G. Retrospective study of 145 supernumerary teeth. *Med Oral Patol Oral Cir Bucal*. 2006;11(4):339–83.
- Mukhopadhyay S. Mesiodens: A clinical and radiographic study in children. *J Indian Soc Pedod Prev Dent*. 2011;29(1):34–8.
- Davis PJ. Hypodontia and hyperdontia of permanent teeth in Hong Kong schoolchildren. *Commun Dent Oral Epidemiol*. 1987;15(4):218–38. doi:10.1111/j.1600-0528.1987.tb00524.x.
- Niswander JD, Sujaku C. Congenital anomalies of teeth in Japanese children. *Am J Phys Anthropol*. 1963;21(4):569–74.
- Akhil JE, Prashant B. Mesiodens: A Case Report and Literature Review. *Inter Ped Dent Open Acc J*. 2018;1(3). doi:10.32474/ipdoaj.2018.01.000113.
- Shih WY, Hsieh CY, Tsai TP. Clinical evaluation of the timing of mesiodens removal. *J Chin Med Association*. 2016;79(6):345–50.
- Sarne O, Shapira Y, Blumer S, Finkelstein T, Schonberger S, Bechor N, et al. Supernumerary teeth in the maxillary anterior region: The dilemma of early versus late surgical intervention. *J Clin Pediatr Dent*. 2018;42(1):55–61.
- Rajab LD, Hamdan MA. Supernumerary teeth: review of the literature and a survey of 152 cases. *Int J Paediatr dent*. 2002;12(4):244–54.
- Garvey MT, Barry HJ, Blake M. Supernumerary Teeth — An Overview of Classification, Diagnosis and Management. *J Can Dent Assoc*. 1999;65(1):612–8.
- Stellzig A, Basdra EK, Komposch G. Mesiodentes: Inzidenz, morphologie, ätiologie. *J Orofac Orthoped Fortschritte der Kieferorthopädie*. 1997;58(3):144–53.
- Kumar GS. *Orban's Oral Histology & Embryology*. India: Elsevier Health Sciences APAC; 2014. p. 35.
- Sivapathasundharam B. *Shafer's Textbook of Oral Pathology-E Book*. Elsevier Health Sciences; 2016. p. 922.
- Gallas MM, García A. Retention of permanent incisors by mesiodens: a family affair. *Brit Dental J*. 2000;188(2):63–7.
- Goksel S, Agirgol E, Karabas HC, Ozcan I. Evaluation of Prevalence and Positions of Mesiodens Using Cone-Beam Computed Tomography. *J Oral Maxillofac Res*. 2018;9(4):1. doi:10.5037/jomr.2018.9401.
- Ashkenazi M, Greenberg BP, Chodik G, Rakocz M. Postoperative prognosis of unerupted teeth after removal of supernumerary teeth or odontomas. *Am J Orthod Dentofac Orthoped*. 2007;131(5):614–23.
- Omer RS, Anthonappa RP, King NM. Determination of the optimum time for surgical removal of unerupted anterior supernumerary teeth. *Pediatr Dent*. 2010;32(1):14–20.
- Leyland L, Batra P, Wong F, Llewelyn R. A retrospective evaluation of the eruption of impacted permanent incisors after extraction of supernumerary teeth. *J Clin Pediatr Dent*. 2006;30(3):225–56.

Author biography

Sanpreet Singh Sachdev, Post Graduate  <https://orcid.org/0000-0001-7655-8180>

Yogita Adhane, Post Graduate

Tabita Joy Chettiankandy, Professor & Head  <https://orcid.org/0000-0002-6839-6959>

Manisha Ahire Sardar, Associate Professor  <https://orcid.org/0000-0003-2003-1544>

Ashwini Chhapane, Post Graduate

Cite this article: Sachdev SS, Adhane Y, Chettiankandy TJ, Sardar MA, Chhapane A. Mesiodens - Obvious yet unnoticed: A case report. *IP Int J Maxillofac Imaging* 2022;8(4):150-153.