

Content available at: <https://www.ipinnovative.com/open-access-journals>

IP Journal of Diagnostic Pathology and Oncology

Journal homepage: <https://www.jdpo.org/>

## Case Report

# Characteristic yet unusual presentation of an odontogenic myxoma in the anterior mandible

Kavita Wadde<sup>1</sup>, Asha Chowdhar<sup>1</sup>, Sanpreet Singh Sachdev<sup>2,\*</sup>, Prachi Mathe<sup>3</sup>

<sup>1</sup>Dept. of Oral and Maxillofacial Surgery, Government Dental College and Hospital, Mumbai, Maharashtra, India

<sup>2</sup>Dept. of Oral Pathology and Microbiology, Government Dental College & Hospital, Mumbai, Maharashtra, India

<sup>3</sup>Dept. of Oral Medicine and Radiology, Government Dental College & Hospital, Mumbai, Maharashtra, India



## ARTICLE INFO

### Article history:

Received 30-09-2022

Accepted 29-11-2022

Available online 14-01-2023

### Keywords:

Odontogenic tumor

Odontogenic mesenchyme

Oral surgery

## ABSTRACT

Odontogenic myxoma (OM) is a rare benign odontogenic tumor characterized by stellate and spindle-shaped cells dispersed in an abundant myxoid extracellular matrix. The bony invasion by the tumor imparts a characteristic ‘soap bubble’, ‘honeycomb’, or ‘tennis racquet’ radiographic appearance to the lesion. The decision of adopting a conservative or radical approach also depends on various factors such as location, size, and duration of the lesion, and age, gender, and expectations of the patient. Therefore, adequate treatment planning is crucial for the management of cases of OM and varies on an individual basis. The present case report described the management of a case of unusually large OM occurring in a 31-year-old Indian female in the mandibular anterior region crossing the midline.

This is an Open Access (OA) journal, and articles are distributed under the terms of the [Creative Commons Attribution-NonCommercial-ShareAlike 4.0 License](https://creativecommons.org/licenses/by-nc-sa/4.0/), which allows others to remix, tweak, and build upon the work non-commercially, as long as appropriate credit is given and the new creations are licensed under the identical terms.

For reprints contact: [reprint@ipinnovative.com](mailto:reprint@ipinnovative.com)

## 1. Introduction

Odontogenic myxoma (OM) is a rare benign odontogenic tumor (OT) accounting for about 3 to 6% of all OTs.<sup>1</sup> It is characterized by stellate and spindle-shaped cells dispersed in an abundant myxoid extracellular matrix.<sup>2</sup> The earliest case of OM in the jaws was described by Thoma and Goldman in 1947.<sup>3</sup> The World Health Organization described it as a slow-growing but locally aggressive tumor derived from the odontogenic ectomesenchyme of a developing tooth or undifferentiated mesenchymal cells in the periodontal ligament.<sup>4</sup>

OM generally tends to occur in the second and third decades of life and exhibits a female predilection.<sup>2,5</sup> Two-thirds of OM occur in the mandible, particularly in the molar region.<sup>2</sup> The tumors occurring in the anterior region are mostly described in the maxilla. Also, the tumor seldom crosses the midline. The bony infiltration

by the tumor imparts a characteristic ‘soap bubble’, ‘honeycomb’, or ‘tennis racquet’ radiographic appearance to the lesion.<sup>5</sup> Characteristics. Thus, most cases of OM appear radiographically as a multilocular lesion with well-defined borders and intervening trabeculae.

Much controversy surrounds the treatment of OM; some investigators believe that a conservative approach should suffice while others recommend a more radical approach. A recurrence rate of about 25% has been reported,<sup>6</sup> which can be attributed to various reasons discussed later. The decision of adopting a conservative or radical approach also depends on various factors such as location, size, and duration of the lesion, and age, gender, and expectations of the patient. Therefore, adequate treatment planning is crucial for the management of cases of OM and varies on an individual basis.

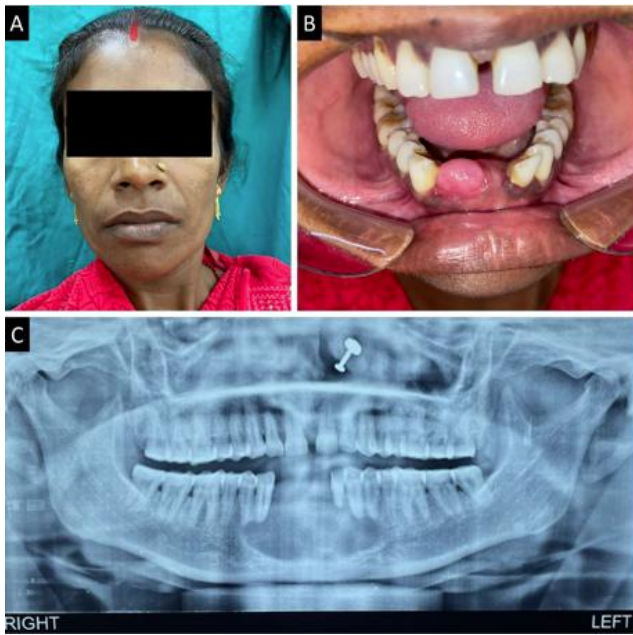Herein, we report the management of a case of unusually large OM occurring in an Indian female in the fourth decade in the mandibular anterior region crossing the midline.

\* Corresponding author.

E-mail address: [sunpreetss@yahoo.in](mailto:sunpreetss@yahoo.in) (S. S. Sachdev).

## 2. Case Report

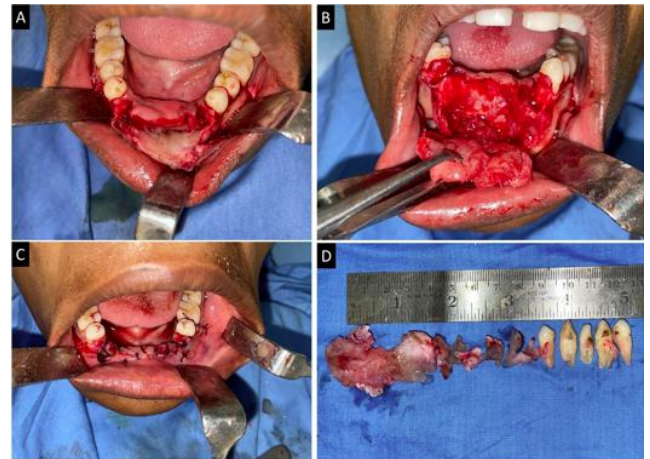
A 31-year-old female presented to the institutional department with an asymptomatic swelling in the mandibular anterior region. The swelling had gradually increased in size over the course of the past two years, swelling in the lower front tooth region of the jaw for 2 years. During this period, three of her mandibular incisors had also spontaneously expelled out from the socket. No history of trauma or medical condition was elicited from the patient. The patient's general examination and vital parameters were unremarkable. No gross asymmetry or enlarged lymph nodes were found on the extraoral observation of the patient.



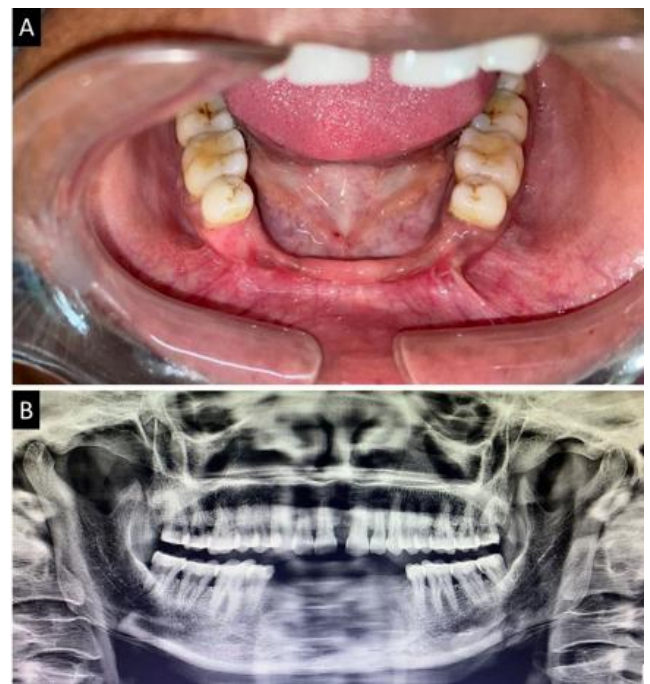
**Fig. 1:** A: Extraoral frontal profile of the patient; B: Diffuse swelling with sessile growth in the mandibular anterior region; C: Orthopantomogram showing a well-defined multilocular lesion.

Intraoral examination revealed a sessile pink-colored growth was noted on the alveolar ridge in the region of missing mandibular right central and lateral incisors. Besides the obvious lesion, expansion of the anterior part of the mandible by canines on both sides, on the buccal as well as the lingual aspect bound was noted. The mandibular left central incisor was also missing, while the lateral incisor exhibited a Grade II mobility. On palpation, the lesion was found to be hard in consistency without any associated tenderness and fixed to the underlying tissues.

Orthopantomogram revealed an extensive well-defined multilocular radiolucent lesion with corticated borders in some areas. The locules were large enough to impart a classic 'soap bubble' appearance to the lesion. Cone beam computed tomography imaging showed an area of infiltration in the medullary bone with thin trabeculae in



**Fig. 2:** A: Exposure of the lesion by vestibular incision; B: Excision of the tumor mass; C: Post-surgical suturing; D: Excised tissues along with the extracted involved teeth



**Fig. 3:** 6-month post-surgical follow-up showing A: Adequate healing without evidence of disease on; A: Clinical inspection, and B: Orthopantomogram.

the anterior region of the mandible and the lesion measured approximately  $30 \times 20 \times 20$  mm.

Syringe and needle aspiration of the lesion did not yield any fluid. An incisional biopsy was performed under local anesthesia. Histopathological examination revealed an abundant myxoid connective tissue stroma consisting of haphazardly arranged stellate- to spindle-shaped cells. Few loosely arranged bundles of collagen fibers were noted. Based on the clinical presentation, characteristic

radiographic appearance, and microscopic picture, a final diagnosis of 'Odontogenic myxoma' was imparted for the case.

The lesion being about 3 cm in maximum dimension, a conservative approach was planned for the management. The lesion was exposed by means of a labial vestibular incision from the left first premolar to the right first premolar. Surgical excision with curettage was done under local anesthesia and the remaining incisors, canines, and first premolars were extracted on both sides. The area was sutured with 3-0 black silk material for 7 days. Macroscopically, the excised mass was brownish-white in color, without encapsulation, and soft in consistency. The cut surface was slimy and gelatinous. Histopathological findings of the excised tissue confirmed those from the incisional biopsy. The patient was put under oral antibiotics and analgesics after the procedure. The patient was instructed to follow a strict soft diet for 15 days, to permit the correct healing of the incision.

The first follow-up was done next following day of surgery and further after 7 and 15 days after surgery. After the clinical examination showed no sign of local complications, the patient was allowed to return to his normal diet and activities. A 2-month follow-up found the patient in good health, with no sign of a local recurrence. After the 6-month post-surgical follow-up, there was no clinical or radiographic evidence of disease or recurrence. The patient was advised for regular follow-up visits every 3 months for the next two years followed by every 6 months thereafter. Prosthetic rehabilitation was also recommended for the patient.

### 3. Discussion

OM has been reported to occur mostly in patients within the age range of 21 to 51 years and a mean age of 31 to 32.4 years has been described.<sup>1,5</sup> While some databases have reported no sexual predilection, some investigators have found that a greater number of cases of OM have occurred in females.<sup>7</sup> Most of the cases do not present any clinical symptoms or at most with only swelling. Our case occurring as an asymptomatic swelling in a 31-year-old female corroborates these findings.

The mandible is affected in two-thirds of cases of OM while only one-third of cases occur in the maxilla, especially with a propensity to occur in the posterior/molar region.<sup>2,5</sup> Those occurring in the anterior region are usually maxillary OMs.<sup>8</sup> Additionally, despite being locally aggressive, anterior OMs seldom cross the midline, and if found to be doing so, are again usually those occurring in the maxilla. In this aspect, our case of OM crossing the midline in the mandibular anterior region is quite a rare occurrence and was similar to a case reported by Ghazali et al.<sup>5</sup>

A lesion appears to be multilocular when the septae of bone are left while the surrounding medullae are

resorbed by the active disease process. OM being non-encapsulated and highly aggressive, substantial infiltration occurs in the adjacent medullary bone owing to the action of hyaluronidase that resorbs hyaluronic acid proteoglycan in the extracellular matrix. Thus, multilocularity is one of the classical radiographic features. The lesions crossing the mid-line are, therefore, only the multilocular OMs.<sup>9</sup> 25% of mandibular OMs present as a well-defined lesion with corticated borders which was observed in our radiograph.<sup>5</sup>

The differential diagnosis of the present case included ameloblastoma, odontogenic keratocyst, cemento-ossifying fibroma, and central giant cell granuloma. Although the characteristic 'soap-bubble' appearance was evident, it is not pathognomonic and thus, such cases need to be differentiated by histopathology. Lesions that demonstrate the microscopic presence of abundant collagen fiber bundles are termed 'odontogenic myxofibroma', however, the present case only contained a sparse number of collagen fibers.<sup>2</sup>

Whether to adopt a conservative or a radical approach while treating an OM is yet a matter of debate. A rate of recurrence of about 25% has been described when using a conservative approach, while none of the cases treated radically have reported a recurrence.<sup>10</sup> Given the aggressive nature of the lesion, the infiltrative portion of the tumor may be left out in a conservative treatment procedure and therefore, account for the number of recurrences noted. Nevertheless, conservative treatment is favored by the patients for several obvious reasons such as preservation of function and aesthetics, shorter hospitalization time, and better feasibility.<sup>6</sup>

In the present case, the lesion occurring in the anterior region of a female required more consideration for the aesthetic aspect. Boffano et al. suggested that conservative treatment such as excision or enucleation and curettage is recommended when the diameter of an odontogenic myxoma is less than 3 cm, whereas a segmental resection with immediate reconstruction is preferred in patients with larger tumors.<sup>11</sup> Therefore, a conservative approach was adopted in the present case keeping in mind the patient's preference and the size of the lesion. Uneventful healing without any evidence of disease was observed after a 6-month post-surgical follow-up in our case indicating a good response by the patient.

### 4. Conclusion

OM is, in itself, a rare OT, and the present case occurring in the mandibular anterior region crossing the midline further added to its unusual presentation. The lesion is locally aggressive and tends to resorb large amounts of bone imparting a characteristic multilocular radiographic appearance. The histopathological picture is quite characteristic comprising an abundant myxoid stroma that may be interspersed with varying proportions of fibrous

elements. The treatment approach to be adopted for OM has to be decided on an individual basis depending on the age of the patient, the region of involvement by the lesion, and the tumor size.

## 5. Source of Funding

None.

## 6. Conflict of Interest

None Declared.

## References

1. Kawase-Koga Y, Saijo H, Hoshi K, Takato T, Mori Y. Surgical management of odontogenic myxoma: a case report and review of the literature. *BMC Res Notes*. 2014;7:214. doi:10.1186/1756-0500-7-214.
2. Takata T, Slootweg PJ. Ameloblastoma. In: El-Naggar A, Chan J, Grandis J, Takata T, Slootweg P, editors. WHO classification of head and neck tumours. Lyon: IARC; 2017. p. 215–8.
3. Nguyen TT, Eo MY, Cho YJ, Myoung H, Kim SM. Large myxomatous odontogenic tumor in the jaw: a case series. *J Korean Assoc Oral Maxillofac Surg*. 2021;47(2):112–9. doi:10.5125/jkaoms.2021.47.2.112.
4. Thoma KH, Goldman HM. Central myxoma of the jaw. *Oral Surg Oral Med Oral Pathol*. 1947;33(7):532–40. doi:10.1016/0096-6347(47)90315-3.
5. Ghazali AB, Arayasantiparb R, Juengsomjit R, Lam-Ubol A. Central Odontogenic Myxoma: A Radiographic Analysis. *Int J Dent*. 2021;p. 1093412. doi:10.1155/2021/1093412.
6. Rocha AC, Gaujac C, Cecchetti MM, Amato-Filho G, Machado GG. Treatment of recurrent mandibular myxoma by curettage and cryotherapy after thirty years. *Clinics (Sao Paulo)*. 2009;64(2):149–52. doi:10.1590/s1807-59322009000200013.
7. Ram H, Mehta G, Kumar M, Lone P. Odontogenic myxoma in a 52-year-old woman. *BMJ Case Rep*. 2014;p. 2013202416. doi:10.1136/bcr-2013-202416.
8. Takahashi Y, Tanaka K, Hirai H, Marukawa E, Izumo T, Harada H, et al. Appropriate surgical margin for odontogenic myxoma: a review of 12 cases. *Oral Surg, Oral Med, Oral Pathol Oral Radiol*. 2018;126(5):404–8.
9. Kauke M, Safi AF, Kreppel M, Grandoch A, Nickenig HJ, Zoeller JE, et al. Size distribution and clinicoradiological signs of aggressiveness in odontogenic myxoma-three-dimensional analysis and systematic review. *Dentomaxillofac Radiol*. 2017;47(2):20170262. doi:10.1259/dmfr.20170262.
10. Leiser Y, Abu-El-Naaj I, Peled M. Odontogenic myxoma-a case series and review of the surgical management. *J Craniomaxillofac Surg*. 2009;37(4):206–9. doi:10.1016/j.jcms.2008.10.001.
11. Boffano P, Gallesio C, Barreca A, Bianchi FA, Garzino-Demo P, Roccia F, et al. Surgical treatment of odontogenic myxoma. *J Craniofacial Surg*. 2011;22(3):982–7.

## Author biography

**Kavita Wadde**, Associate Professor

**Asha Chowdhar**, Post Graduate

**Sanpreet Singh Sachdev**, Post Graduate

**Prachi Mathe**, Post Graduate

**Cite this article:** Wadde K, Chowdhar A, Sachdev SS, Mathe P. Characteristic yet unusual presentation of an odontogenic myxoma in the anterior mandible. *IP J Diagn Pathol Oncol* 2022;7(4):272-275.