

See discussions, stats, and author profiles for this publication at: <https://www.researchgate.net/publication/364344368>

Role of Nidogen-2 in diagnosis and prognosis of head and neck squamous cell carcinoma: A systematic review

Article in *Journal of Oral and Maxillofacial Pathology* · October 2022

DOI: 10.4103/jomfp.jomfp_293_22

CITATIONS

2

READS

20

6 authors, including:



Tabita Joy Chettiankandy

Government Dental College And Hospital, Mumbai

61 PUBLICATIONS 181 CITATIONS

[SEE PROFILE](#)



Sanpreet Singh Sachdev

Nair Hospital Dental College

63 PUBLICATIONS 38 CITATIONS

[SEE PROFILE](#)

Some of the authors of this publication are also working on these related projects:

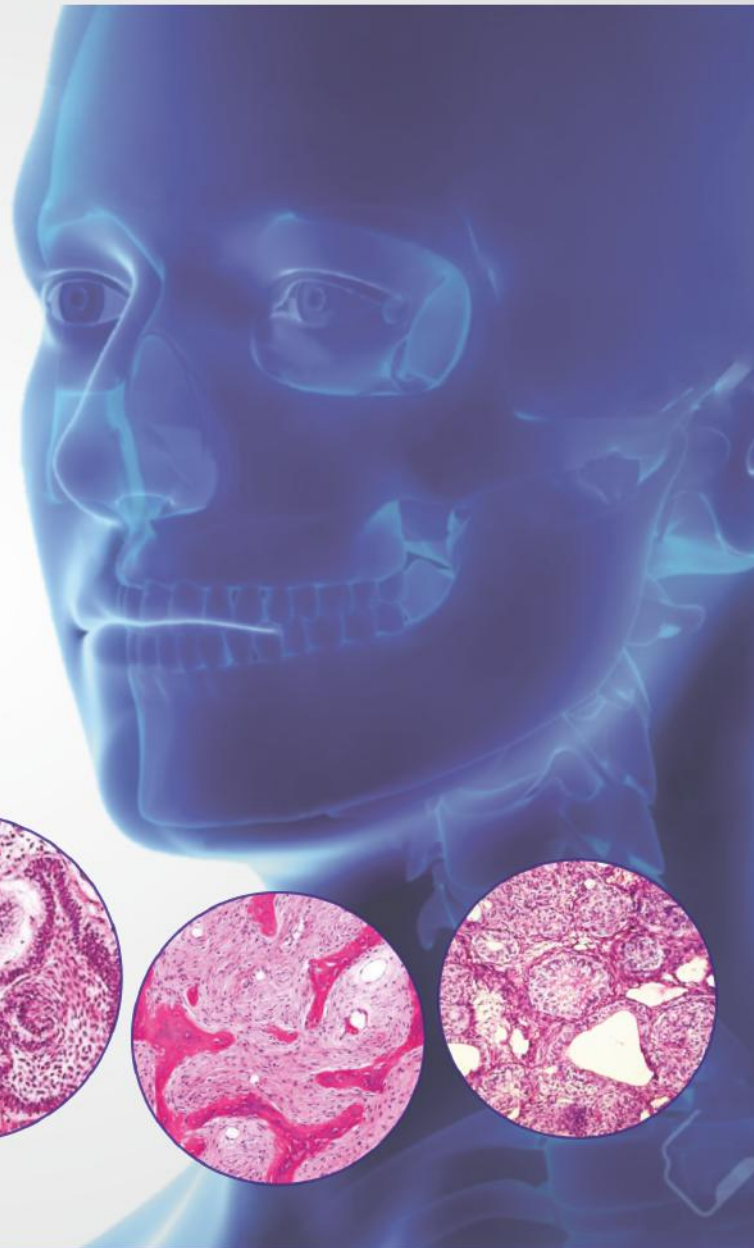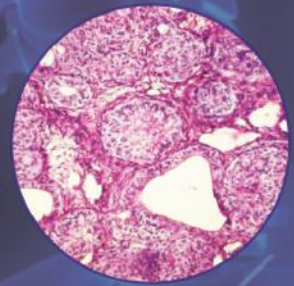
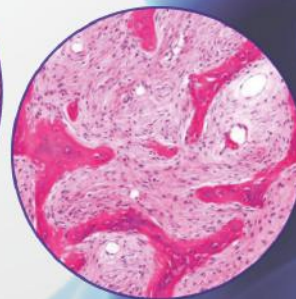
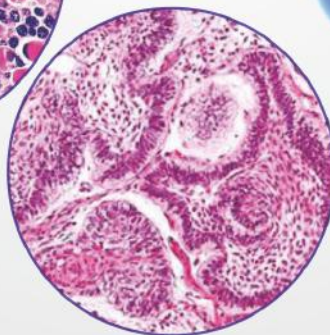
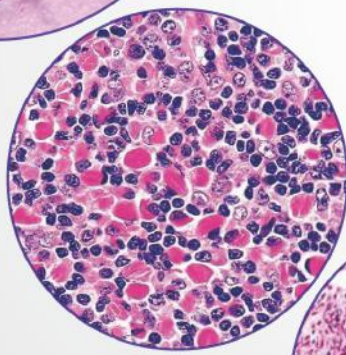
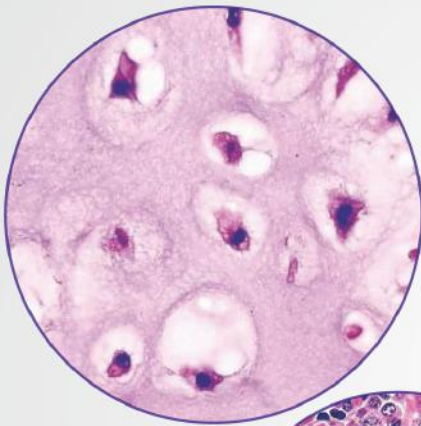


Forensic View project



Oral Surgery View project

JOURNAL OF _____ **Volume 26 ■ Issue 3 ■ July-September 2022**
ORAL AND MAXILLOFACIAL PATHOLOGY



JOMFP
www.jomfp.in

The Official Publication of Indian Association of Oral and Maxillofacial Pathologists

Role of Nidogen-2 in diagnosis and prognosis of head and neck squamous cell carcinoma: A systematic review

Tabita Joy Chettiankandy¹, Sanpreet S. Sachdev¹, Shubhangi P. Khandekar², Alka Dive², Deepak Nagpal³, Jagdish V. Tupkari¹

¹Department of Oral Pathology and Microbiology, Government Dental College and Hospital, Mumbai, Maharashtra, ²Department of Oral Pathology and Microbiology, VSPM's Dental College and Research Centre, Nagpur, Maharashtra, ³Department of Oral Pathology and Microbiology, Swargiya Dadasaheb Kalmegh Smruti Dental College and Hospital, Nagpur, Maharashtra, India

Abstract

Context: Nidogen-2 (*NID-2*) hypermethylation has been implicated in many types of cancers, such as lung, bladder, and gastric carcinomas. However, its role has not yet been studied adequately in head and neck squamous cell carcinomas (HNSCC). HNSCCs constituting a major portion of the global cancer load, it is of importance to diagnose and treat them at earliest. This systematic review was performed to assess the role of *NID-2* in HNSCCs and assess its utility as a diagnostic and prognostic marker.

Materials and Methods: A systematic search was performed across multiple databases to identify studies pertaining to analysis of expression or methylation of *NID-2* in HNSCCs. The sample size, type of cancer/premalignant condition studied, type of tissue/fluid analysed, and the various methodologies used and their results were extracted. PROSPERO registration number: CRD42021245326.

Results: Four studies were identified after a systematic search of literature. The studies analysed *NID-2* expression or methylation in conditions such as nasopharyngeal carcinoma, esophageal carcinoma, and oral squamous cell carcinoma (OSCC). *NID-2* was found to be a highly specific marker for HNSCCs, and serum *NID-2* levels also correlated with poor survival.

Conclusion: Data from the reviewed studies indicate that hypermethylation of *NID-2* is highly specific for HNSCC. The high specificity is maintained in salivary and serum samples, facilitating accurate and non-invasive prognostication of HNSCC. The relatively lower sensitivity of *NID-2* methylation may be overcome by analysing it along with a panel of multiple biomarkers such as HOX-A2 and YKL20.

Keywords: Epigenetics, hypermethylation, oral squamous cell carcinoma, salivary biomarkers

Address for correspondence: Dr. Sanpreet S. Sachdev, 301, Department of Oral Pathology and Microbiology, Government Dental College and Hospital, P D' Mello Road, Fort, Mumbai – 400 001, Maharashtra, India.

E-mail: sunpreetss@yahoo.in

Submitted: 25-Apr-2022, **Revised:** 09-May-2022, **Accepted:** 06-Jul-2022, **Published:** 17-Oct-2022

INTRODUCTION

Head and neck squamous cell carcinomas (HNSCCs) constitute about 4–10.3% of all the cancers. About 90% of HNSCCs comprise oral squamous cell

carcinoma (OSCCs), making it the most prevalent cancer of the oral cavity.^[1,2] It has been demonstrated that a 6-month delay in diagnosis of OSCC can reduce the chances of survival to half.^[3] Therefore, it is of utmost

This is an open access journal, and articles are distributed under the terms of the Creative Commons Attribution-NonCommercial-ShareAlike 4.0 License, which allows others to remix, tweak, and build upon the work non-commercially, as long as appropriate credit is given and the new creations are licensed under the identical terms.

For reprints contact: WKHLRPMedknow_reprints@wolterskluwer.com

How to cite this article: Chettiankandy TJ, Sachdev SS, Khandekar SP, Dive A, Nagpal D, Tupkari JV. Role of Nidogen-2 in diagnosis and prognosis of head and neck squamous cell carcinoma: A systematic review. J Oral Maxillofac Pathol 2022;26:382-8.

Access this article online

Quick Response Code:



Website:

www.jomfp.in

DOI:

10.4103/jomfp.jomfp_293_22

importance to diagnose OSCC in the initial stages of development.

OSCC is generally preceded by various oral potentially malignant disorders (OPMDs), such as oral leukoplakia (OL), erythroplakia, oral submucous fibrosis, and oral lichen planus (OLP) in 80% of cases.^[4] OL is the most commonly noted OPMD with a malignant transformation rate of about 2%. It is characterised by dysplastic changes in the epithelium along with hyperkeratinisation. The severity of dysplastic changes has a clinical implication wherein it is indicative of the risk of transition of OL to OSCC. Therefore, identifying the risk of transition would definitely help in determining an apt treatment plan for each case.

A well-coordinated balance exists between the epithelium and the connective tissue stroma, under normal circumstances. Maintenance of cell adhesive junctions between the epithelial cells and the support provided by extracellular matrix (ECM) to the connective tissue is crucial for maintaining this balance. The basement membrane (BM) also helps in maintaining the integrity of these tissue elements through complex molecular signalling pathways.^[5] A breach in the BM and subsequent infiltration of epithelial cells into the underlying stroma is considered as the hallmark of squamous cell carcinoma. Increased proliferation and migratory capacity of cells, coupled with the degradation of BM and ECM, together increase the invasiveness of the cells ultimately leading to tumour progression and metastasis.

Amongst the various genes involved in the BM–ECM signalling, Nidogen-2 (*NID-2*) has been recently identified as a more suitable biomarker for normal or cancerous state. The protein products of *NID-2* gene stabilise the BM by linking collagen IV and laminin to the fibrillar network present in the ECM. They also play a role in maintenance of cell adhesion by connecting to membranous integrins.^[6] *NID-2* is also considered as a tumour suppressor gene (TSG) as it decreases the colony formation and migratory ability of the epithelial cells.^[7] Loss of *NID-2* expression due to aberrant hypermethylation of its promoters leads to degradation of BM and ECM, and also increases the invasive ability of the epithelial cells. Consequently, loss of expression of *NID-2* has been implicated in various malignant neoplasms, such as gastric, lung, and bladder carcinomas.^[7,8]

In the head and neck region, *NID-2* can be detected in tissues, saliva, and serum.^[9,10] Amongst 301 potential TSGs, *NID-2* hypermethylation was found to be one of the most specific and sensitive biomarkers for detection

of HNSCC.^[9] Even so, the number of studies investigating expression of *NID-2* in HNSCCs is very limited. In this article, the studies published in scientific literature that have investigated the expression or functional role of *NID-2* in HNSCC or OPMDs were systematically reviewed. This systematic review serves to answer the question “does Nidogen-2 play a role in diagnosis and prognosis of HNSCC and OPMDs?” The objective of this review is to discern the feasibility and reliability of *NID-2* as a diagnostic and prognostic marker for the most prevalent cancerous and pre-cancerous conditions.

MATERIALS AND METHODS

The review title and search protocol are registered in the International Prospective Register of Systematic Reviews – PROSPERO under the registration number CRD42021245326.^[11] A systematic search for studies pertaining to expression of *NID-2* in HNSCC or leukoplakia was performed in the following databases: Medline (Ovid), PubMed, PubMed Central, Web of Science Citation Index Expanded, (SCIEXPANDED), and Google Scholar. The keywords comprised ((Nidogen) OR (NID-2)) AND ((HNSCC) OR Cancer OR OSCC. A second search comprised the keywords ((Nidogen) OR (NID-2)) AND Leukoplakia OR OPMD OR premalignant OR precancer. The cross-references cited in the retrieved literature were also screened for identification of possible studies, in case if any were missed by the search strategy.

The abstracts of search results were screened, and full text articles of the potential studies were scrutinised. Cross-sectional as well as longitudinal studies were considered as eligible for the review that comprised case–control or cohort studies as well as randomised clinical trials. To minimise the risk of bias, the PROBAST tool for assessment of the Risk of Bias and Applicability of Prediction Model Studies was used.^[12] To further minimise bias in quality assessment, the authors were divided into two groups (Sanpreet S. Sachdev and Tabita Joy Chettiankandy; Shubhangi P. Khandekar and Alka Dive) that independently evaluated the case reports for their inclusion in this review.

Data extraction

The sample size, type of cancer/premalignant condition studied, type of tissue/fluid analysed, and the various methodologies used to analyse the expression of *NID-2* were extracted. The expression of *NID-2* noted in normal tissues, OL, and OSCC by various methods used was recorded along with their sensitivity and specificity. The interpretation of results by the respective authors with respect to functional role or clinical significance of *NID-2* in OL or OSCC

was also elicited. Demographic, clinical, radiological, and histopathological features of all the cases were extracted. The quality of articles included in the review was also assessed using the GRADE approach.^[13] The extracted data were entered and tabulated into worksheets (Microsoft Office Excel 2016, Redmond, Washington, USA).

RESULTS AND DISCUSSION

The systematic search revealed four studies pertaining to analysis of expression or methylation of *NID-2* [Figure 1].^[7,9,10,14] The data extracted from these studies has been tabulated in [Table 1]. The most comprehensive demonstration of role of *NID-2* in suppressing tumorigenesis was done in the study performed by Chai *et al.*^[7] They demonstrated reduced colony-forming ability to an extent of 43.4% in the cell lines expressing *NID-2*, by means of 2D and 3D colony formation assays. Even so, *NID-2* re-expression was unable to induce significant changes in both the *in vitro* cell proliferation and *in vivo* tumorigenicity of the cancer cells. Re-expression of *NID-2*, however, significantly reduced the migration ability and relative invasiveness of the cells.

Furthermore, on intrasplenic injection of metastatic cancer cells, metastases were found in the liver of 90% of control mice but not in those expressing *NID-2*.

They also demonstrated weaker expression of *NID-2* in Nasopharyngeal Carcinoma (NPC) compared to that noted in non-neoplastic glands of nasopharyngeal mucosa, by means of Immunohistochemistry (IHC). Overall, their study revealed that although *NID-2* was unable to induce cell proliferation, it suppressed the colony formation, migration, and invasiveness of the cancerous cells.

Aberrant promoter hypermethylation of TSGs has been demonstrated to play a critical role in tumorigenesis in various types of cancer.^[15] Promoter hypermethylation of TSGs was also demonstrated to be present in premalignant lesions as well as HNSCC, serving as a potential biomarker for early detection.^[9] Furthermore, DNA is a highly stable molecule, making it a suitable candidate for studying methylation status of biomarkers. Chai *et al.*^[7] also demonstrated a downregulation in *NID-2* expression in 100% NPC and 80% Esophageal squamous cell carcinoma (ESCC) cell lines.

Guerrero-Preston *et al.*^[9] observed hypermethylation of potential TSGs in HNSCC and compared it to leukoplakia and normal tissues. They found that *EDNRB*, *HOXA9*, *GATA4*, *NID-2*, *KIF1A*, and *DCC* genes showed significant differential methylation between OSCC and normal tissues. Of these, the classification performance of *HOXA9* and *NID-2* was found to be better than the other genes owing to

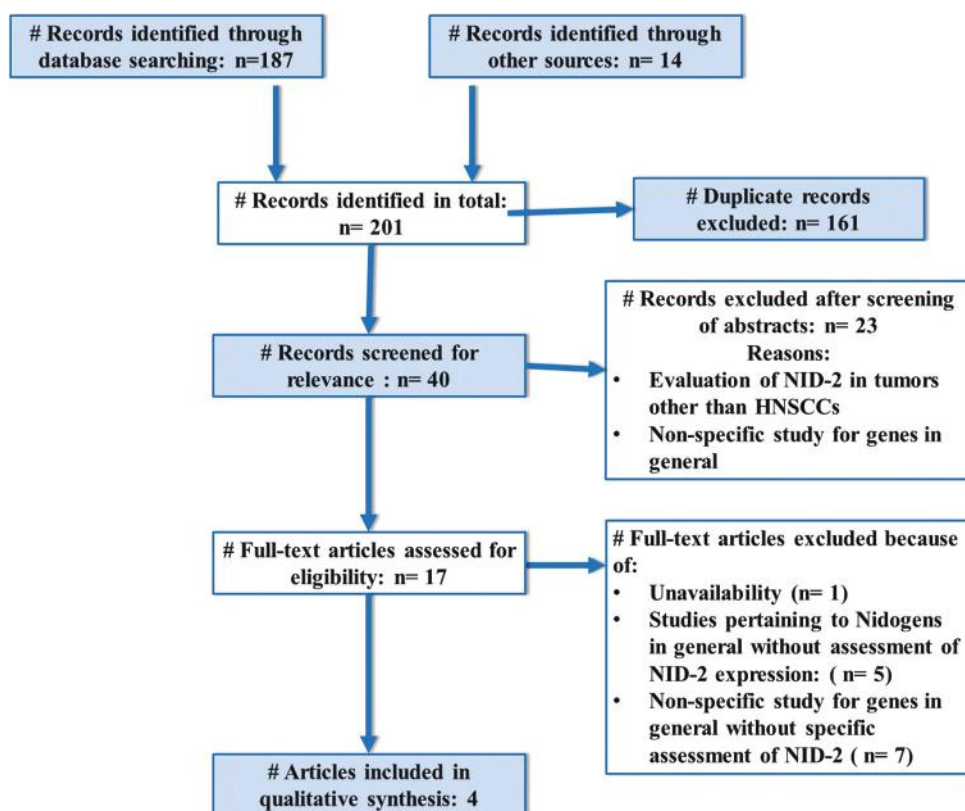


Figure 1: PRISMA flow chart indicating selection process of articles for final qualitative synthesis of this systematic review

Table 1: Summary of studies pertaining to *MID-2* expression in HNSCC

		Study Design, Methods, and Results		Inferences	
Author	Guerrero-Preston et al. ^[9]	Hybridised bisulfite-converted DNA from tissues	Saliva	Minimal or no promoter methylation of <i>MID-2</i> was	
Country	Chile	Discovery screen	Discovery screen	observed in the normal oral cavity mucosa samples, whereas varying degrees of	
Total sample	179	Method used: qMSP		hypermethylation	
Type of conditions	OSCC/OPSCC and leukoplakia	n=36, 24 OSCC 12 normal	n=51, 16 OSCC, 16 OPSCC, 19 normal	Differential methylation in a subset of genes shows a progression to	
Types of samples	Tissue and saliva	Sensitivity=71% Specificity=100% AUC=0.79 ICA=80% k=0.60	OPSCC: Sensitivity=72% Specificity=21% AUC=0.57 ICA=59% k=0.55	hypermethylation in OSCC samples when compared with normal and leukoplakia samples	
Author	Chai et al. ^[7]	Tissues: 50 NPC, 17 ESCC, and 50 adjacent non-cancer tissues	Cell lines: 7 NPC and 15 ESCC	<i>MID-2</i> is significantly methylated and its expression is downregulated in cancer tissues	
Country	China	Methylation-sensitive high-resolution melting (MS-HRM) analysis: Methylation in 74% NPC and 80% ESCC, 34% adjacent non-cancer tissues	qPCR: <i>MID-2</i> downregulated in 100% NPC and 80% ESCC cell lines	Adjacent apparently normal tissues also exhibit epigenetic modifications in <i>MID-2</i>	
Total sample	129	Immunohistochemistry: Stronger staining was observed in the nuclei of the non-neoplastic glands of nasopharyngeal mucosa compared to NPC	2D and 3D colony formation assays <i>MID-2</i> -expressing cell lines had reduced colony-forming ability, 43.4% of the control.	<i>MID-2</i> plays an important role in metastasis suppression, despite it not affecting primary tumour growth.	
Type of conditions	NPC/ESCC	<i>In vitro</i> migration chamber assay: <i>MID-2</i> -expressing cell lines had reduced migration ability, 68% of the control	Matrigel-coated invasion chambers Cell lines expressing <i>MID-2</i> had reduction in relative invasiveness, 68% of the control	Re-expression of <i>MID-2</i> suppresses the colony-forming ability, migration, and invasiveness of cancerous cells	
Types of samples	Tissue and cell lines	<i>In vitro</i> cell proliferation assay and <i>in vivo</i> subcutaneous nude mouse tumorigenicity assay: <i>MID-2</i> re-expression was unable to induce significant changes in both the <i>in vitro</i> cell proliferation and <i>in vivo</i> tumorigenicity of the cancer cells	Intraspinal injection of metastatic cancer cells and monitoring by live animal imaging system: Vector controls with metastasis in live liver (90%), no metastasised tumours observed in the <i>MID-2</i> group (0 of 12 mice; 0%; P value=0.0001)		
Author	Chai et al. ^[10]	Method used: Sandwich ELISA	Sample groups: 101 ESCC and 50 Normal Controls	Significant findings	
Country	China	Results:		Serum <i>MID-2</i> level is a significant	
Total sample	151	Median serum <i>MID-2</i> level: in ESCC=24.35 µg/L; in controls= 15.85 µg/L.		prognosis factor, independent of the	
Type of conditions	ESCC	At a threshold level for ESCC= 18.05 µg/L		tumour stage	
Types of samples	Serum	Sensitivity=71% Specificity=64%		The elevation of serum <i>MID-2</i> level can distinguish the ESCC patients from the healthy controls, with an AUC of 0.756	
		Statistically significant elevation of serum <i>MID-2</i> levels among ESCC patients (P=4.3e-09)			
		Early stage ESCC patients (Stages I and II, n=29) had significantly elevated serum <i>MID-2</i> levels as compared to the controls (P=0.00063)			
		High serum <i>MID-2</i> level (>32.60 µg/L) was significantly associated with poorer survival (Hazard ratio=1.984)			

Contd...

Table 1: Contd...

		Study Design, Methods, and Results	Inferences
Author	Srisuttee et al. ^[14]	Method used: duplex real-time PCR	
Country	Thailand	Oral Rinse (n=90): 40 smokers, 40 OSCC patients, and 50 healthy controls Nidogen methylation was detected in 79.07% of OSCC cases. Sensitivity=79.07% Specificity=100% On comparing the same cases in which swab and rinse, both were obtained: Twenty of 22 cases in oral swab were methylated (77.3%).	<i>NID-2</i> methylation was an altered specific condition that was observed in OSCC but not in normal mucosa, smokers, and OLP epithelium. The assessment of methylation status in <i>NID-2</i> is a potential OSCC screening method using samples collected from non-invasive methods such as oral rinse and swab approaches.
Total sample	255	Oral Swab (n=90): 30 oral lichen planus, 22 OSCC patients, and 50 healthy controls Nidogen methylation was detected in 90.91% of OSCC cases. Sensitivity=90.91% Specificity=100%	
Type of conditions	OSCC		
Types of samples	Oral rinse and Oral swab		

qMSP=quantitative methylation specific PCR, OSCC=oral squamous cell carcinoma, HNSCC=head and neck squamous cell carcinomas, AUC=Area under curve, ICA=Inter-class agreement, NPC=Nasopharyngeal carcinoma, ESCC=Esophageal squamous cell carcinoma, OPSCC=Oropharyngeal squamous cell carcinoma, ELISA=Enzyme-linked immunosorbent assay

high sensitivity (>70%) and specificity (100%). The several methylated loci harboured by *NID-2* in the CpG islands have conferred it to be a top hit promoter hypermethylated gene in NPC as well as ESCC.^[9,16]

Transcriptomic data with respect to *NID-2* mRNA as well as proteomic microarray analysis have revealed that hypermethylation is present in cancerous tissues, and its demethylation suppresses the events associated with tumour progression, such as proliferation, migration, and invasion of neoplastic cells.^[17] Results from real-time PCR performed by Srisuttee et al.^[14] indicated that the *NID-2* methylation did not occur over time; supported by the fact that it was absent in the epithelia of smokers as well as patients with OLP. They also found no significant correlation between *NID-2* expression and the clinical stage or histological grade of OSCC. Their findings suggested that hypermethylation of *NID-2* occurred only when the normal epithelial cells completely transformed into cancerous cells.

On the contrary, Guerrero-Preston et al.^[9] demonstrated a gradual increase in hypermethylation from normal to premalignant to cancerous state by means of quantitative methylation specific PCR (qMSP), supporting the association of the level of hypermethylation of *NID-2* with carcinogenesis. Further support for the gradual methylation of *NID-2* from normal to cancerous state was provided by Chai et al.^[7] They found that methylation of *NID-2* was present in not only the cancerous tissues but also 34% of the tissues adjacent to NPC or ESCC by means of methylation-sensitive high-resolution melting analysis. The mutagenic changes occurring in the cancerous area also get transmitted to the adjacent apparently normal mucosa, which may later develop the tumour phenotype. The gradual methylation noted in adjacent apparently normal tissues occurs because of field cancerisation.^[18]

Histopathological examination of the tissue obtained by means of biopsy is currently the gold standard for diagnosing OSCC. The biopsy procedure is invasive, tends to cause patient discomfort, and may even impair functioning.^[19] The histopathological processing of the sampled tissue further requires generous efforts on the part of laboratory personnel and pathologists. Consequently, recent emphasis has shifted on potentially non-invasive modes for diagnosis. These include detection of biomarkers in saliva or serum, which are readily obtained. Analysis of biomarkers is now possible at a genomic or proteomic level without the need of a waiting period needed for histopathological processing. The techniques having developed only recently, the data pertaining to specificity and sensitivity of detecting

biomarkers in these fluids through various techniques are quite limited.^[10,14]

Saliva is a rich source of information when considering the cancers occurring in the oral cavity, as it is constantly in contact with the tumour cells. Guerrero-Preston *et al.* analysed salivary *NID-2* methylation in OSCC and Oropharyngeal squamous cell carcinoma (OPSCC) patients by qMSP.^[9] A higher sensitivity of the method was found for diagnosing OSCC patients (87%) compared to those with OPSCC (72%). This discrepancy could be attributable to the different aetiological factors of both the lesions. While OSCC commonly arises because of accretion of genetic mutations resulting from tobacco or alcohol, OPSCC is largely related to human papilloma virus.^[20] Another contributing factor could be the difference in the extent to which saliva contacts the oral cavity and oropharynx.

Overall, a salivary sample obtained from the oral cavity would contain more representative cells with *NID-2* hypermethylation compared to the oropharynx, accounting for the difference in sensitivity. The specificity of detecting *NID-2* hypermethylation in salivary samples was found to be much lower (21%) and with low inter-classification agreement ($k = 0.23$), compared to tissue specimens (specificity = 100%, $k = 0.60$). Unlike other sites, such as oesophagus or nasopharynx, the oral cavity is readily accessible, which facilitates obtaining swabs from the tumour area.

Srisuttee *et al.*^[14] detected *NID-2* methylation in OSCC patients and observed a 100% specificity by both the methods. They also found that the oral swab method was more sensitive (90.91%) compared to oral rinse (79.07%). However, oral swab could only be obtained from patients with an obvious lesional area, thereby limiting its application as a screening or diagnostic procedure. Care must also be taken to ensure that the clinical technique for obtaining swab is proper and covers the cells beyond the necrotic tissue over the lesion, to avoid a false-negative outcome. Furthermore, obtaining oral swab is more invasive compared to oral rinse and may cause physical discomfort for the patients.

The source of *NID-2* in serum is largely unknown although a few theories have been postulated.^[10] Considering the fact that the BM is disrupted in carcinomas, the *NID-2* linked with integrins could be carried into the bloodstream along with the other disintegrated components. It is also possible that the tumour microenvironment may not be a major source of serum *NID-2*, and only contributes a small

amount of the protein. The downregulation of *NID-2* noted in the ECM may be sensed by stromal or endothelial cells. A feedback mechanism signalling the cells to replenish the *NID-2* in ECM may be triggered, which could account for the elevated levels of the protein in serum.

Chai *et al.*^[10] observed significantly elevated serum *NID-2* levels in patients with ESCC compared to healthy individuals by means of Enzyme-linked immunosorbent assay (ELISA). They also classified the patients into three groups – “high” (32.60 µg/L), “medium” (20.0–32.60 µg/L), and “low” (<20.0 µg/L) based of their serum *NID-2* levels. It was found that “high” serum *NID-2* levels were associated with poorer survival rate with a hazard ratio of 1.984. There was no correlation noted between the serum *NID-2* level and clinicodemographic factors, such as age, gender, Tumor-Node-Metastasis stage, or histopathological grade of the tumour. Their results pointed towards the effective yet limited utility of serum *NID-2* as a diagnostic as well as prognostic marker.

The sensitivity and specificity of serum *NID-2* as a diagnostic biomarker for tumours did not significantly outperform other existing biomarkers, such as *YKL20*, *CEA*, *CYFRA21-1*, and *SCCA*.^[21] In their study, Guerrero-Preston *et al.*^[9] also reported an improved sensitivity (94%) and specificity (97%) when analysing hypermethylation of *HOXA2* and *NID-2* together as a panel, compared to the individual genes. Therefore, future studies can analyse and correlate expression of *NID-2* and other specific biomarkers such as *YKL20* by means of methods such as multiplex IHC. Such studies would yield a highly sensitive and specific panel, ultimately improving the diagnosis and prognostication of HNSCCs.

Another clinical applicability of analysing *NID-2* expression would be to evaluate the effectivity of cancer therapy. Care must be taken, however, to avoid false-positive or false-negative outcomes when assessing post-chemotherapy margins of the tumour. It is possible that the drugs used may alter the biochemistry of tissues yielding unreliable results. In general, epigenetic alterations are related, to some extent, to systemic conditions. Disorders causing damage to mucosa BM may be able to induce false-positive results. Other systemic conditions or viral infections may also cause epigenetic alterations leading to uncertain predictability of the methylation status.^[22] Because *NID-2* is only hypermethylated when the tissue cells completely transit into cancer cells, a negative detection in dysplastic or non-invasive aggressive lesions must not be trifled with. At present, because of limited number of studies, *NID-2* expression in OPMDs

and other systemic conditions such as AIDS is largely unknown. An extensive study of *NID-2* in various diseased states and validation across laboratories would minimise this bias or error in assessment in future.

CONCLUSION

NID-2 is a tumour suppressor gene playing a vital role in limiting the invasive ability of cells. The studies analysing *NID-2* expression or methylation in HNSCC patients are very limited. Data from the reviewed studies indicate that hypermethylation of *NID-2* is a highly specific and sensitive marker for HNSCC. The high specificity is maintained in salivary and serum samples, facilitating accurate and non-invasive prognostication of HNSCC. The relatively lower sensitivity of *NID-2* methylation may be overcome by analysing it along with a panel of multiple biomarkers, such as *HOX-A2* and *YKL20*. Further studies with respect to *NID-2* methylation in OPMDs and systemic conditions would further improve the diagnostic and prognostic utility of *NID-2*.

Financial support and sponsorship

Nil.

Conflicts of interest

There are no conflicts of interest.

REFERENCES

1. Global Cancer Observatory, India. 2020. Available from: <https://gco.iarc.fr/today/data/factsheets/populations/356-india-fact-sheets.pdf>. [Last accessed on 2021 Sep 26].
2. Bagan JV, Scully C. Recent advances in oral oncology: Epidemiology, aetiopathogenesis, diagnosis and prognostication. *Oral Oncol* 2008;44:103-8.
3. Akbulut N, Oztas B, Kursun S, Evirgen S. Delayed diagnosis of oral squamous cell carcinoma: A case series. *J Med Case Rep* 2011;5:1-4.
4. Ranganathan K, Kavitha L. Oral epithelial dysplasia: Classifications and clinical relevance in risk assessment of oral potentially malignant disorders. *J Oral Maxillofac Pathol* 2019;23:19-27.
5. Kim SH, Turnbull J, Guimond S. Extracellular matrix and cell signalling: The dynamic cooperation of integrin, proteoglycan and growth factor receptor. *J Endocrinol* 2011;209:139-51.
6. Salmivirta K, Talts JF, Olsson M, Sasaki T, Timpl R, Ekblom P. Binding of mouse nidogen-2 to basement membrane components and cells and its expression in embryonic and adult tissues suggest complementary functions of the two nidogens. *Exp Cell Res* 2002;279:188-201.
7. Chai AWY, Cheung AKL, Dai W, Ko JMY, Ip JCY, Chan KW, et al. Metastasis-suppressing NID2, an epigenetically-silenced gene, in the pathogenesis of nasopharyngeal carcinoma and esophageal squamous cell carcinoma. *Oncotarget* 2016;7:78859-71.
8. Yegin Z, Gunes S, Buyukalpelli R. Hypermethylation of TWIST1 and NID2 in tumor tissues and voided urine in urinary bladder cancer patients. *DNA Cell Biol* 2013;32:386-92.
9. Guerrero-Preston R, Soudry E, Acero J, Orera M, Moreno-López L, Macía-Colón G, et al. NID2 and HOXA9 promoter hypermethylation as biomarkers for prevention and early detection in oral cavity squamous cell carcinoma tissues and saliva. *Cancer Prev Res (Phila)* 2011;4:1061-72.
10. Chai AW, Cheung AK, Dai W, Ko JM, Lee NP, Chan KT, et al. Elevated levels of serum nidogen-2 in esophageal squamous cell carcinoma. *Cancer Biomark* 2018;21:583-90.
11. Chettiankandy T, Khandekar S, Dive A, Tupkari J. Role of Nidogen-2 in oral leukoplakia and oral squamous cell carcinoma. PROSPERO 2021 CRD42021245326. Available from: https://www.crd.york.ac.uk/prospero/display_record.php?ID=CRD42021245326.
12. Wolff RF, Moons KG, Riley RD, Whiting PF, Westwood M, Collins GS, et al. PROBAST: A tool to assess the risk of bias and applicability of prediction model studies. *Ann Intern Med* 2019;170:51-8.
13. Granholm A, Alhazzani W, Møller MH. Use of the GRADE approach in systematic reviews and guidelines. *Br J Anaesth* 2019;123:554-9.
14. Srisuttee R, Arayataweegool A, Mahattanasakul P, Tangjaturonrasme N, Kerekhanjanarong V, Keelawat S, et al. Evaluation of NID2 promoter methylation for screening of oral squamous cell carcinoma. *BMC Cancer* 2020;20:1-9.
15. Nishida N, Nagasaka T, Nishimura T, Ikai I, Boland CR, Goel A. Aberrant methylation of multiple tumor suppressor genes in aging liver, chronic hepatitis, and hepatocellular carcinoma. *Hepatology* 2008;47:908-18.
16. Esteller M. CpG island hypermethylation and tumor suppressor genes: A booming present, a brighter future. *Oncogene* 2002;21:5427-40.
17. Wang J, Zhao Y, Xu H, Ma J, Liang F, Zou Q, et al. Silencing NID2 by DNA hypermethylation promotes lung cancer. *Pathol Oncol Res* 2020;26:801-11.
18. Mohan M, Jagannathan N. Oral field cancerization: An update on current concepts. *Oncol Rev* 2014;8:244.
19. Mercadante V, Paderni C, Campisi G. Novel non-invasive adjunctive techniques for early oral cancer diagnosis and oral lesions examination. *Curr Pharm Des* 2012;18:5442-51.
20. Lechner M, Liu J, Masterson L, Fenton TR. HPV-associated oropharyngeal cancer: Epidemiology, molecular biology and clinical management. *Nat Rev Clin Oncol* 2022;19:306-27.
21. Yang Y, Huang X, Zhou L, Deng T, Ning T, Liu R, et al. Clinical use of tumor biomarkers in prediction for prognosis and chemotherapeutic effect in esophageal squamous cell carcinoma. *BMC Cancer* 2019;19:526.
22. Djomkam Zune AL, Olwal CO, Tapela K, Owoicho O, Nganyewo NN, Lyko F, et al. Pathogen-induced epigenetic modifications in cancers: Implications for prevention, detection and treatment of cancers in Africa. *Cancers (Basel)* 2021;13:6051.