

See discussions, stats, and author profiles for this publication at: <https://www.researchgate.net/publication/350351425>

Complications Of Distraction Osteogenesis– Narrative Review

Article in *Oral Surgery* · March 2021

DOI: 10.1111/ors.12613

CITATIONS

4

READS

73

6 authors, including:



Prajwalit Kende

Government Dental College And Hospital, Mumbai

30 PUBLICATIONS 59 CITATIONS

[SEE PROFILE](#)



Ashish Sarda

Government Dental College And Hospital, Mumbai

11 PUBLICATIONS 13 CITATIONS

[SEE PROFILE](#)



Nimma Vijayalaxmi

Government Dental College And Hospital, Mumbai

25 PUBLICATIONS 176 CITATIONS

[SEE PROFILE](#)

Complications of distraction osteogenesis: Narrative review

Prajwalit P. Kende¹ | Ashish Sunilkumar Sarda¹  | Harsh Desai¹ | Jayant Landge¹ |
Vijayalaxmi Nimma² | Varthangpuii Varte¹

¹Department of Oral and Maxillofacial Surgery, Government Dental College and Hospital, Mumbai, India

²Department of Oral Medicine and Radiology, Government Dental College and Hospital, Mumbai, India

Correspondence

Ashish Sunilkumar Sarda, Department of Oral and Maxillofacial Surgery, Government Dental College and Hospital, P D'Mello Road, Near CSMT, Fort, Mumbai, Maharashtra 400001, India.

Email: ashish.sarda08@gmail.com

Abstract

Aim: The aim of this narrative review is to discuss the complications of distraction osteogenesis (DO) of facial skeleton and their management.

Materials and Method: A detailed literature search was done on PubMed, Google Scholar and Embase from the year 1990 onwards. Any systematic review, randomized controlled trial, controlled clinical trial, retrospective/prospective study discussing about complications of maxillofacial DO and their management were included.

Results: Complications related to DO were divided based on phases as (a) planning (patient counselling, improper vector, errors in device selection, etc.), (b) surgery (tooth injury, neurosensory disturbance, incomplete osteotomy, etc.), (c) distraction (device failure, pain at regenerate site, premature consolidation, etc.) and (d) consolidation (infection, hypertrophic scar, relapse, etc.).

Conclusion: Widespread applications are possible with DO though it is a device-dependent and technique-sensitive procedure. With proper planning and execution, DO can become the gold standard for managing various maxillofacial disorders.

KEYWORDS

complications, distraction osteogenesis, management, maxillofacial

Clinical Relevance

Scientific rationale for study- Distraction osteogenesis is gaining widespread acceptance as a preferred substitute to orthognathic surgery in the treatment of spectrum of craniofacial anomalies. It is considered to be a new tool in biomedical engineering requiring technical expertise showing promising clinical success.

Principal findings- Virtual surgical planning has minimized complications to a greater extent as it provides an idea to the operator to achieve proper vector of distraction.

Practical implication- This narrative review aims to thoroughly discuss the complications of distraction osteogenesis of the facial skeleton with their prevention and management. Also, this review will enable the beginners in the field to tackle these complications more efficiently.

INTRODUCTION

'Distraction osteogenesis (DO) is a biological process of new bone formation that occurs between the bone segments that are separated by gradual incremental traction.'¹ Initiation of this process starts with the application of incremental traction

to the reparative callus, which ultimately will join the divided bone segments and continue as long as the tissue is stretched. The tension generated by traction stimulates new bone formation within the gap parallel to the vector of distraction. DO can be used for correction of skeletal deformities, craniofacial syndromes, replacement of missing jaw bones and facial

asymmetry. In general, there are four phases of DO, namely, planning, surgery, distraction and consolidation.

A complication is an unexpected deviation from the treatment plan that, without appropriate correction, will lead to worsening of the existing, development of a new, or recurrence of the initial pathologic process.² The complications of DO were classified by several authors who discussed their severity, ways of preventing them and need of intervention if needed.

This narrative review aims to thoroughly discuss the complications of DO of the facial skeleton with their prevention and management. Also, this review will enable the beginners in the field to tackle these complications more efficiently. Comprehensive flowcharts are given which will enable the beginners in the field to tackle the complications of DO more efficiently.

HISTORICAL BACKGROUND

DO was first performed by Codivilla³ in 1905 to lengthen femurs in a series of patients with malformed legs. In the 1950s, a Russian orthopaedic surgeon named Gavril Ilizarov⁴ improved the technique, applying it to the long bones of the lower extremities. Since then, many surgeons have contributed the application of DO in maxillofacial region which are summarized in Table 1.

MATERIAL AND METHODOLOGY

A detailed literature search was done on PubMed, Google Scholar and Embase from year 1990 onwards. Keywords used were 'maxillofacial distraction osteogenesis' AND 'complications' AND 'classification'. Any systematic review, randomized controlled trial, controlled clinical trial (CCT), retrospective/prospective study discussing about complications of maxillofacial DO were included. All the selected literatures were screened, assessed and analysed. Literatures discussing DO other than maxillofacial region were excluded.

DISCUSSION

DO has become an alternative to traditional osteotomies and bone grafting for skeletal expansion. Wide application of DO for correction of common dentofacial deformities is somewhat hampered by the cumbersome nature, lengthy treatment protocols and lack of accurate three-dimensional control of the distraction vector. These issues are responsible, at least in part, for most complications that occur in DO cases. Various classifications of complications of DO given in literature are discussed in Table 2. To discuss the complications with their prevention and management, we broadly divided them based on phases of DO as given in Table 3.

TABLE 1 Historical background of distraction osteogenesis

Codivilla ³	First to describe the technique of bone lengthening by DO
Ilizarov ⁴	Developed techniques of bone transportation and limb lengthening using external ring fixator
Snyder et al ⁵	Applied this technique to mandibular canine region using modified external fixator device
Bell and Epker ⁶	Described the technique of rapid palatal expansion to increase the maxillary width in cases of transverse deficiency
Guerrero and Bell ⁷	Described an intraoral symphyseal osteotomy for widening of mandible
McCarthy et al ⁸	First clinical application in literature for mandibular lengthening in patients with hemifacial microsomia and Nager's syndrome
Monasterio et al ⁹	Simultaneous mandibular and maxillary distraction in hemifacial microsomia

Abbreviation: DO, distraction osteogenesis.

Complications related to planning phase

Patient counselling

Lengthy treatment periods required in DO may lead to developing non-compliance on the patient's part (Figure 1). There are chances that a non-compliant patient may activate the device more often or not at all leading to problems with regenerate formation. Similarly, the patient or their parents may depict lack of compliance with regard to maintenance of adequate oral hygiene and following dietary instructions given. Troulis and Kaban¹⁵ reported that the device may be turned in wrong direction causing unfavourable changes in the developing regenerate bone. The broad range of consequences can range from trifle ones like wound dehiscence, acute inflammation/localised infection to significant ones like developing malocclusion and loosening or dismantling of the device.

Management

1. Counselling and encouraging the patient and family regarding the possible length of the stay necessary during the course of treatment, accurate device activation, oral hygiene maintenance and a healthy diet.
2. Maintaining a stringent recall schedule during the entire treatment period.

Improper vector

Inappropriate distraction vectors lead to long-term complications and may result in failure of surgery if not sufficiently managed. Inadequate preoperative planning and improper device orientation may bring about various types of malocclusion like laterognathism (presenting as cross

TABLE 2 Different classification systems of complications of distraction osteogenesis

Sr no.	Author	Year	Classification	Classification discusses	Classification does not discuss
1	Cherkashin and Samchukov ²	2001	(i) Mistakes (iatrogenic and patient related) (ii) Complications (regenerate malformations, axial deviations, soft-tissue overstretching and infection)	<ul style="list-style-type: none"> • The complications based on phases of distraction osteogenesis. • Iatrogenic and patient related mistakes. • The time of occurrence 	<ul style="list-style-type: none"> • Severity of complication • Need of urgency of complication management
2	Gracia et al ¹⁰	2002	(i) Intraoperative (ii) During distraction (iii) Post distraction	<ul style="list-style-type: none"> • Complications based on the phases of distraction. • The treatment options for the specific complication • Consequences 	<ul style="list-style-type: none"> • Tissues involved • Need of urgency of complication management • The complications related to preoperative phase
3	Shetye et al ¹¹	2009	(i) Minor Incident (ii) Moderate incident (iii) Major incident	<ul style="list-style-type: none"> • -Need of intervention • -Severity of complications 	<ul style="list-style-type: none"> • Complications based on individual stages of DO • Need of urgency of complication management • Tissues involved
4	Norholt et al ¹²	2011	(i) No complications (ii) Minor complications (iii) Moderate complications (iv) Major complications Subclassification a. Hardware related b. Hard and soft tissue related	<ul style="list-style-type: none"> • Severity of complications • Tissue involvement and hardware 	<ul style="list-style-type: none"> • The time of occurrence of each complication • Need of urgency of complication management • The complications based on phases of distraction osteogenesis
5	Dunaway et al ¹³	2012	(i) Major (ii) Moderate (iii) Intermediate (iv) Minor	<ul style="list-style-type: none"> • Intervention for the complications • Severity of complications 	<ul style="list-style-type: none"> • The time of occurrence of each complication • The complications based on stages of distraction osteogenesis • Need of urgency of complication management • Tissues involved
6	Verlinden et al ¹⁴	2015	(i) Type 1. Spontaneously resolving complications (ii) Type 2. Medically or technically manageable complication, without hospitalization (iii) Type 3. Surgically manageable complication requiring local anaesthesia only, without hospitalization (iv) Type 4. Technical complication, necessitating general anaesthesia for correction (v) Type 5. Medically or surgically manageable complication with hospitalization or general anaesthesia (vi) Type 6. Permanent sequelae, functionally and/or psychosocially disabling and unachieved goal or unsatisfactory result	<ul style="list-style-type: none"> • Technical and surgical management of complications • Intervention for the complications • The type of anaesthesia needed • Sequelae of complications 	<ul style="list-style-type: none"> • The time of occurrence of each complication • The complications based on phases of distraction • Need of urgency of complication management

Abbreviation: DO, distraction osteogenesis.

bite(s)), anterior open bite, resorption of the condyle(s) and subsequently contributing towards development/worsening of temporomandibular joint disorders (TMDs). It is largely dependent on the type of distractor used, occlusal interferences and influence of muscles of mastication. Master et al¹⁶ reported inappropriate distraction vector in five patients undergoing unidirectional distraction ($n = 56$) and in six patients undergoing bidirectional distraction ($n = 85$).

Management

1. Success or failure of DO is often determined by a combination of accurate preoperative clinical planning along with a thorough radiographical assessment that eventually helps in determining the osteotomy and device location.¹⁷
2. Virtual surgical planning (VSP) plays an important role in the execution of a vector of distraction. On the virtual model, osteotomies are completed, and the distraction

TABLE 3 Complications related to phases of distraction osteogenesis

Sr no.	Phase of distraction	Complications
1	Planning	Patient selection and counselling, improper vector, errors in device selection and inadequate device length
2	Surgery	Tooth injury, neurosensory dysfunction, incomplete osteotomy and fracture of bone
3	Distraction	Device failure, pain at regenerate site, premature consolidation and interference due to device
4	Consolidation	Infection, hypertrophic scar, incomplete ossification, regenerate fracture, relapse and TMJ disorders

movement is simulated. From these data, the magnitude and path of movement and the position and orientation of the distraction device are determined.¹⁸

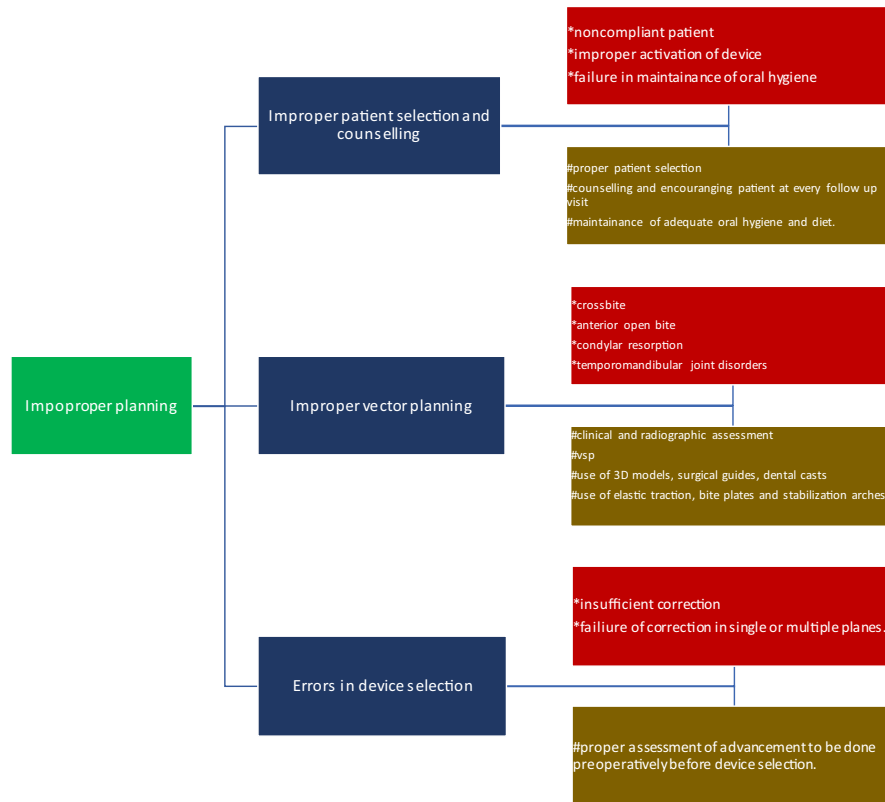
3. Also, the use of 3D models,¹⁹ surgical guides¹⁵ and dental casts help in planning the vector of distraction. Intermaxillary

and/or maxillomandibular elastic traction, bite plates and stabilization arches should be used to mould the newly formed regenerate and optimize developing occlusion.

Role of VSP in planning DO

Three-dimensional printing and the virtual models allow surgeon to predetermine the location of device, footplates and implant screws, also giving an idea about the osteotomy and any modification if needed. Also, as the desired advancements can be visualized, the length of distraction and vector planning can be easily carried out avoiding further complications due to unwanted interferences.²⁰ A prospective study done by Chen et al²¹ concluded that VSP can aid in facilitated treatment planning, an accurate osteotomy, repositioning of bony segments and contouring of the mandibular border in the treatment of TMJ ankylosis and secondary mandibular deformity. In the study by Yu et al²² on eight patients and concluded that computer-assisted surgical planning and intraoperative virtual guide shows its great value in improving the accuracy of DO and restoring facial symmetry. It is regarded as a valuable technique in this potentially complicated procedure. According to Resnick,²³ VSP and 3D printing of cutting

Flowchart 1 (Complications related to planning phase)



(*consequences; #prevention/ management)

FLOWCHART 1 Complications related to planning phase (*consequences; # prevention/management)

guides for intraoperative use are likely to improve precision, decrease operative time and improve outcome for infants with Robin sequence undergoing mandibular distraction.

Inadequate device length and error in device selection

As previously mentioned, planning plays a crucial role in the selection of proper device and their length. Inadequate device length can cause insufficient correction (lengthening or failure in asymmetry correction). Error in device selection can lead to failure during correction in single or multiple planes.

Management

1. The length to be advanced should be judged based on clinical findings and radiographic evaluation. Devices should then be selected based on the amount of movement required, considering overcorrection in all cases to compensate for relapse.
2. Selection of appropriate device based on planned correction of the deformity in single or multiple planes.

Intraoperative complications

Tooth injury

Presence of impacted tooth buds in the line of osteotomy or alternatively in the area of fixation of the device lies at a high risk of unintentional iatrogenic injury (Figure 2). Freitas et al²⁴ evaluated injuries to the molar teeth and buds in patients presented with various facial anomalies who were operated for mandibular DO with mean age of 8.1 years and found various consequences related to tooth injury which are highlighted in Table 4.

Management

1. Preoperative osteotomy site planning should be done using radiographs, VSP and fabrication of surgical guides keeping in mind the position of the tooth bud.
2. In cases of expected/unexpected tooth bud interferences along the osteotomy line, an oblique osteotomy design should be adopted as far as possible.

Neurosensory dysfunction

Surgical approach for placement of the device has reported transient paraesthesia of the marginal mandibular nerve. Causes of inferior alveolar nerve injury include (a) direct injury during osteotomy and distraction device application or device fixation elements and (b) indirect damage such as focal nerve compression by progressive oedema or device fixation elements.² Wijbenga et al²⁵ reported incidence of neurosensory dysfunction in 57 patients ($n=91$) after mandibular DO, which either resolved completely or reduced to a slightly altered

sensory function. Symptoms ensuring thereafter include paraesthesia, loss of sensation and motor function, sometimes secondary to a short period of soft-tissue oedema, sensory hyperesthesia and motor dysfunction in the affected nerve.

Management

1. If nerve injury occurred during surgery, the entire treatment plan must be reevaluated including adjustment of the amount of lengthening and the distraction rate.
2. However, to circumvent the resulting neurosensory disturbance during distraction, one can decrease the rate of distraction lengthening to facilitate healing.
3. Usually, the long-term result of chronic nerve overstretching is positive, although the period of restoration of the lost nerve function and rehabilitation process may require more than a year.

Incomplete osteotomy

An incomplete osteotomy may ultimately lead to failure in obtaining the amount/type of correction and distortion/failure of the distractor. The usual manifestations that develop include severe pain at the osteotomy site, failure in activating the device leading to eventual distortion in the device framework or loosening of the footplate screws. At this juncture, an appreciable disparity will be evident between the actual days of distractor activation and the visible movement of the bony segments.¹⁵

Management

To prevent this complication, the distractor should be activated intraoperatively to ensure completeness of the osteotomy evident as equal bony separation between the cortices. It is then reversed before wound closure.

1. In undetected cases of incomplete osteotomy, reoperation, however, becomes the only viable solution.

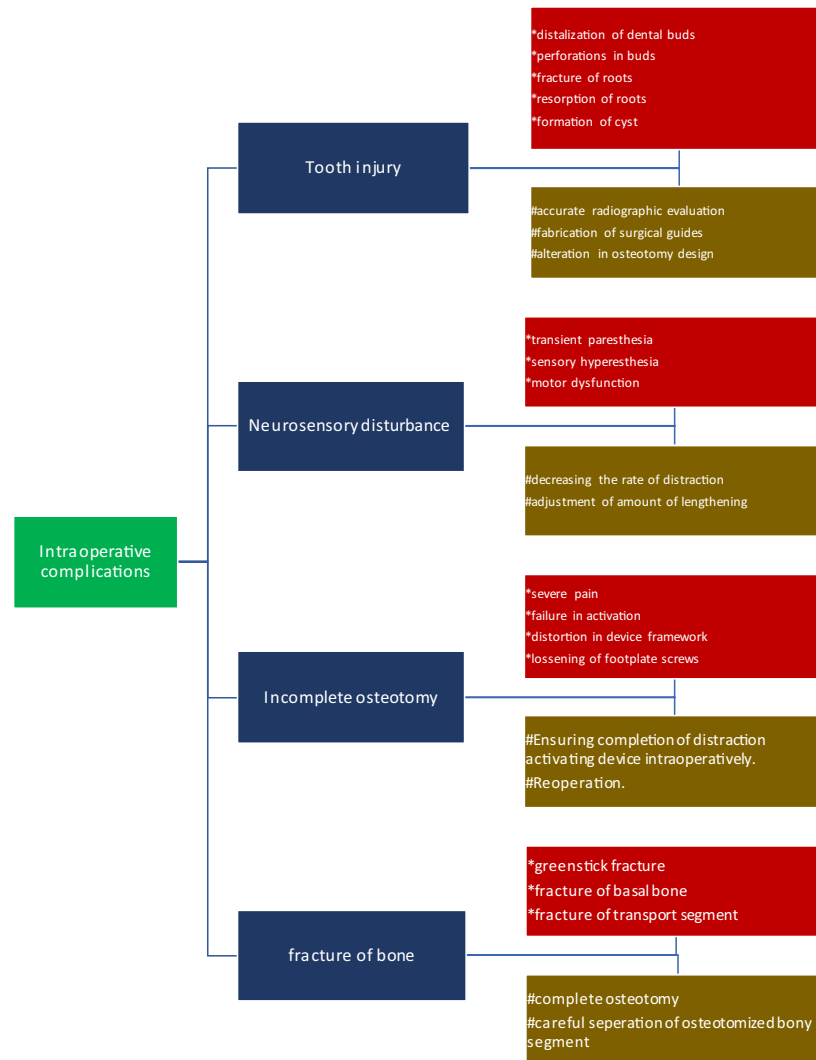
Fracture of bone

Due to inappropriate osteotomy, there is a high chance of unfavourable fracture to one or both the cortices. Excessive force delivered during completion of osteotomy can cause an unfavourable fracture of the segment. This fracture can add to the complexity of the surgery and the need for further reduction and fixation. Fractures of bone are frequently seen when creating transport bone segments in cases of transport distraction osteogenesis (TDO). It may range from greenstick fracture, fracture of basal bone or transport segment.

Management

1. Checking the completeness of osteotomy.
2. Correct use of osteotome and mallet.
3. Controlling the force delivered during separation of the osteotomized bony fragments.

Flowchart 2 (Intraoperative complications)



(*consequences; # prevention/management)

FLOWCHART 2 Intraoperative complications (*consequences; # prevention/management)

TABLE 4 Consequences following tooth injury—Freitas et al²⁴

Consequences	Incidence (n = 34)
Distalization of the dental bud	11
Migration of distalized molars to their original position within 1–2 years	9
Molar buds sustaining perforations	4
Root injuries leading to resorption	2
Formation of dentigerous cyst	1

Complications related to distraction phase

Device failure

The term device failure encompasses two broad entities, including device breakage/distortion and loosening/dislodgement (Figure 3). A cumulative incidence of 7.5% (n = 1166)

has been reported in literature for these two entities.²⁶ Device breakage has been attributed to premature consolidation, improper activation, external trauma to the device and unmanaged/neglected occlusal discrepancies.²⁷

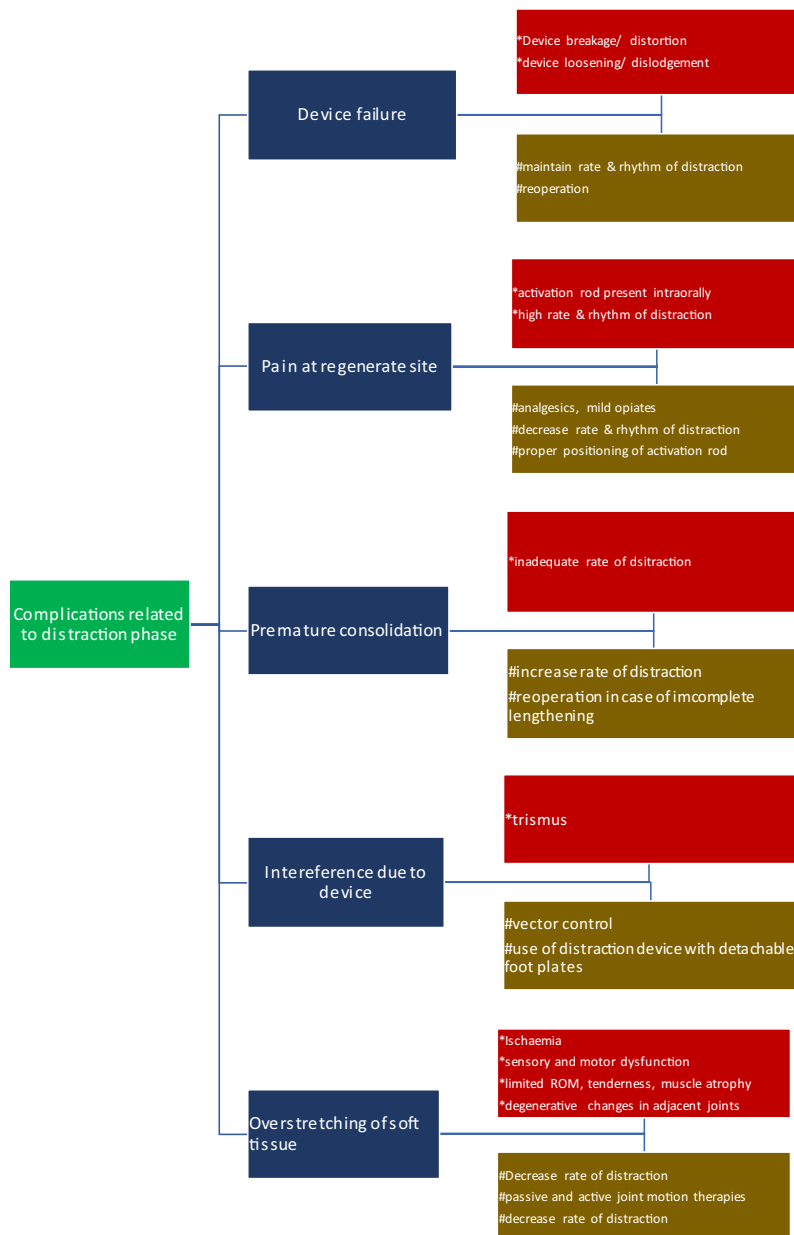
Management

1. This complication often requires a second surgical procedure to treat premature ossification and to replace the non-functional/ distorted/loosened device.
2. Adherence to the standard rate (1 mm/day) and rhythm (0.25 mm × 4/0.5 mm × 2) of the distraction is of utmost importance.

Pain at regenerate site

Pain and functional problems are a common finding concerning DO.²⁸ Norholt et al¹² stated that high number of patients

Flowchart 3 (complications related to distraction phase)



(*consequences; #prevention/ management)

FLOWCHART 3 Complications related to distraction phase (*consequences; # prevention/management)

encountered problems in activating the device, mostly due to high rate and rhythm of DO, but none of them failed to complete the procedure. The activation rod of submerged device is brought out intraorally which can be difficult to access and can cause pain or discomfort to the surrounding soft tissues.

Management

1. Measures should be taken to ease access to the distraction device by fixing the activation arm in a proper position, choosing a proper length of the distraction arm and ensuring thorough instruction of the patient.

2. Administration of sufficient doses of analgesics and in case of severe pain mild opiate throughout the active distraction phase.
3. Rate and rhythm of the device should be decreased.

Premature consolidation

Normally, the distraction regenerate mineralizes from the outer margins towards the centre.²⁹ However, a radiolucent fibrous interzone is always present at the centre of regenerate during distraction. The disappearance of the interzone

during distraction indicates premature consolidation of the regenerate. Causes of premature consolidation include an inadequate rate of distraction and compressive forces on one side of the regenerate leading to early contact between osteotomized segments. In this situation, the operator will notice that the distractor becomes increasingly difficult to turn.

Management

1. In case of low rate of DO, the daily rate of distraction should be increased.
2. In the case of multidirectional devices used for lengthening and asymmetry correction, distracting linearly approximately 10 mm is necessary before adjusting the device in a varus/valgus direction.⁷
3. Reoperation when premature consolidation leads to incomplete lengthening of the jaws.

Interference due to device

Most complications reportedly involving the TMJ are related to decreased mobility during the distraction process. In the retrospective study done by Norholt et al¹² of patients undergoing mandibular DO, trismus was observed in 9.9% ($n = 131$) of the patients owing to the extension of the activated distraction device under the zygomatic arch. Also, in case of maxillary DO, trismus can be observed owing to interference of distraction arm with coronoid process. Depending on the anatomy and vector of distraction, interferences could be present during removal that was not an issue during insertion (i.e., in cases of vertical lengthening of the ramus, the proximal footplate could end up under the zygomatic arch).

Management

1. Proper preoperative planning and vector control can effectively minimize the interferences occurring in the distraction phase.
2. With the advent of semiburied distraction devices with detachable footplates, a second operation for device removal is no longer required.¹⁵

Overstretching of soft tissues

Soft-tissue overstretching may be caused due to (a) inappropriate distraction forces and (b) native compression by the anchoring elements of distractor. The damage to various soft tissues like blood vessels, peripheral nerves, skeletal muscles and adjacent joints can vary with the same amount of tension.

Effect on blood vessels

Though blood vessels can tolerate high distraction rates, they are least tolerant to compressive forces. Due to the pressure exerted by distractor elements obstruction of blood flow can occur resulting in ischaemia.

- Management.*
1. Discontinue the distraction while neutralizing the tension.
 2. Reactivation of distraction after the ischaemia subsides, at half the previous rate.
 3. In severe cases, angiographic evaluation may be needed.

Effect on peripheral nerves

As already stated, focal nerve compression due to the oedema or the fixation elements may cause indirect damage to peripheral nerves which may result in sensory and motor dysfunction. This can be managed by continuing the distraction but at a slower rate.

Effect on skeletal muscle

Muscle overstretching can be one of the major limiting factors for the amount of lengthening via DO as it may result in limited range of motion, tenderness, joint contracture and pain. If the rate of distraction is not altered, it may subsequently result in muscle atrophy, contracture and subluxation with the joint.

- Management.*
1. Secondary surgeries and long periods of rehabilitation may be required.
 2. Passive and active joint motion therapies should be started along with the distraction.
 3. If the range of joint motion is significantly reduced and combined with other clinical signs of muscle overstretching, distraction should be interrupted and continued at a reduced rate, but only after restoration (even partially) of joint range of motion and muscle function.

Effect on adjacent joints

Focal areas of cartilage atrophy and necrosis may occur as a result of progressive compression which may lead to degenerative changes. If not decreased, may lead to deformation of the bone in vicinity progressing to permanent damage of joint function.

- Management.*
1. Decreasing the rate of distraction and unloading the joint with elastics may prevent compression of cartilage.
 2. Cases with congenitally abnormal joints and with known joint pathology should be evaluated carefully.²

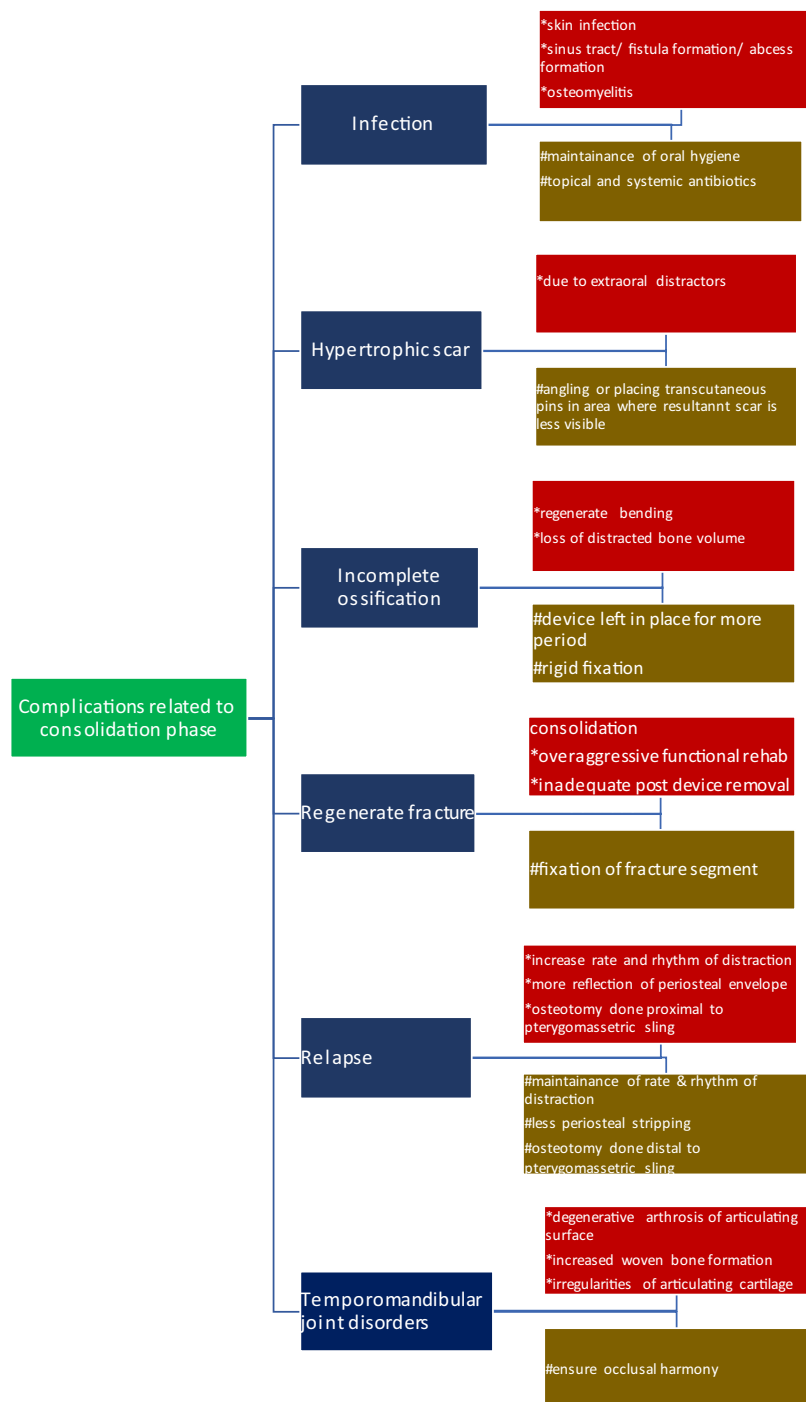
Complications related to consolidation phase

Infection

Infection is one of the concerning complications which can arise during various phases of distraction (Figure 4). They may routinely present as minor superficial skin infections, sinus tract/fistula/abscess formation or severe ones like regenerate site infection ultimately progressing to osteomyelitis. Shetye et al¹¹ have given a 24% ($n = 141$) incidence of infection and defined it as a minor complication, which can be managed by non-invasive measures.

Causes of infections could range from the following:

Flowchart 4 (complications related to consolidation)



(*consequences; #prevention/ management)

FLOWCHART 4 Complications related to consolidation (*consequences; # prevention/management)

1. Inadequate stability of the device and footplate screws during fixation.
2. Failure of oral hygiene measures.
3. Persistence of the activation port of the distractor (serving as a potential pathway of infection) during consolidation.

4. Minor infections also depend upon the type of distraction device used and the quality of the bone being distracted.

Management

1. Maintenance of optimal hygiene, topical and systemic antibiotic coverage.

2. In case of extraoral devices, maintenance of absolute stability of the fixation pins in the bone, as well as tightness of the device.
3. Device on the pins should be checked at each follow-up appointment.
4. In case of submerged intraoral devices, absolute stability of the footplates to the bone should be checked at the time of surgery.
5. The risk of late infections can be reduced if the activation arm can be disconnected after the active distraction phase. This is, however, not possible with all systems.

Hypertrophic scar

Linear cutaneous scars are developed during the distraction period when using extraoral devices. These scars occur more frequently with devices that produce a long fistulous tract.

Management

1. Scarring can be minimized by angling and/or placing transcutaneous pins in an area where the resultant scar will be less visible.
2. Also, the skin can be pinched together along the path of the device before pin placement to minimize scar formation.

Incomplete ossification

Inadequate regenerate ossification can be an expected sequela in patients of older age, habitual smokers, compromised oral hygiene conditions and those with irradiated jaw(s). With higher rate of distraction, the bone may form poorly and may appear radiographically porous, thin or shaped like an hourglass. In this case, if the distraction device is removed before the complete mineralization of the newly formed bone, the stretch of the surrounding muscles and soft tissues overcomes the internal strength of the incompletely ossified regenerate thereby leading to regenerate bending or loss of the distracted bone volume.⁵

Management

1. The device should be left in place until a cortical outline of the distraction regenerate is visible radiographically.
2. If it is necessary to remove the device, a rigid fixation plate can be placed.³⁰

Regenerate fracture

It can be caused due to (a) inadequate duration of the consolidation period, (b) overaggressive functional rehabilitation during the remodelling period, (c) inadequate post-device removal immobilization when indicated and (d) excessive force applied to bone segments.

Management. 1. Due to enhanced vascularization, regenerate fractures usually heal much faster than regular bone fractures. Therefore, the treatment of regenerate

fracture should be initiated immediately to prevent the consolidation of bone segments in an unreduced position.

2. Management of regenerate fracture is similar to that applied for regular fractures.

Relapse

Relapse, as stated, is most commonly associated with maxillofacial DO. Causes of relapse include increased rate and rhythm of distraction, more reflection of periosteal envelope and placing the osteotomy cut proximal to pterygomasseteric sling in case of mandibular body distraction. van Strijen et al³¹ concluded that patients with high mandibular plane angle are at increased risk for developing relapse. Relapse can present clinically as quantitative or qualitative failures in the correction(s) achieved and subsequent development of occlusal discrepancies during consolidation.

Management

1. Decreasing the rate and rhythm of distraction.
2. Less periosteal stripping.

Temporomandibular joint disorders

Specifically, TMJ sequelae have been noticed following mandibular distraction in older and syndromic patients who have pre-existing condylar pathologies, including degenerative arthrosis of the articulating surfaces, increased woven bone formation, irregularities of the articulating cartilage and decreased temporomandibular joint space.³² Schlund et al³³ in their retrospective study evaluated three patients with TMJ ankylosis concluding its higher chances in patients with congenitally deformed TMJ. He also suggested the use of costochondral graft as an alternative in these cases.

Management

Occlusal harmony should be ensured beginning from the planning phase through the consolidation phase.

LIMITATIONS OF DO

Though DO has gained wide popularity for bony deficiencies related to the craniofacial skeleton, several limitations may postpone or abandon its application. They include cost, length of treatment, technique sensitivity, the need for a second surgery to remove distraction devices, patient compliance and social issue due to visibility of the devices.

CONCLUSION

As DO has become widely used within a limited period and as the potential for complications is significant, it is

important to gain increased knowledge about it. However, all of these complications can be minimized or avoided in most cases with accurate preoperative planning, stringent surgical principles and thorough postoperative management. With all this taken into consideration, DO can be considered as a gold standard treatment with widespread applications.

ORCID

Ashish Sunilkumar Sarda  <https://orcid.org/0000-0002-1503-5009>

REFERENCES

- Cope JB, Samchukov ML, Cherkashin AM. Mandibular distraction osteogenesis: a historic perspective and future directions. *Am J Orthod Dentofacial Orthop.* 1999;115(4):448–60. [https://doi.org/10.1016/s0889-5406\(99\)70266-0](https://doi.org/10.1016/s0889-5406(99)70266-0)
- Cherkashin A, Samchukov M. Potential mistakes and complications. In: Samchukov ML, Cope JB, Cherkashin AM, editors: *Craniofacial Distraction Osteogenesis*. St. Louis: Mosby, Inc; 2001:581–94.
- Codivilla A. On the means of lengthening, in the lower limbs, the muscles and tissues which are shortened through deformity. 1904. *Clin Orthop Relat Res.* 1994;301:4–9.
- Ilizarov GA. The tension-stress effect on the genesis and growth of tissues. Part I. The influence of stability of fixation and soft-tissue preservation. *Clin Orthop.* 1989a;238:249–81.
- Synder CC, et al. Mandibular lengthening by gradual distraction. *Plast Reconstr Surg.* 1973;51:506–8.
- Bell WH, Epker BN. Surgical orthodontic expansion of the maxilla. *Am J Orthod.* 1976;70:517.
- Guerrero CA, Bell WH, Contasti GI, Rodriguez AM. Mandibular widening by intraoral distraction osteogenesis. *Br J Oral Maxillofac Surg.* 1997;35:383–92. [http://dx.doi.org/10.1016/s0266-4356\(97\)90712-9](http://dx.doi.org/10.1016/s0266-4356(97)90712-9)
- McCarthy JG, Schreiber JS, Karp NS, Thorne CH, Grayson BH. Lengthening the human mandible by gradual distraction. *Plast Reconstr Surg.* 1992;89:1–10.
- Ortiz Monasterio F, Molina F, Andrade L, Rodriguez C, Arregui JS. Simultaneous mandibular and maxillary distraction in hemifacial microsomia in adults: avoiding occlusal disasters. *Plast Reconstr Surg.* 1997;100:852.
- Garcia AG, Somoza Martin M, Gandara Vila P, et al. Minor complications arising in alveolar distraction osteogenesis. *J Oral Maxillofac Surg.* 2002;60:496–501.
- Shetye PR, Warren SM, Brown D, Garfinkle JS, Grayson BH, McCarthy JG. Documentation of the incidents associated with mandibular distraction: introduction of a new stratification system. *Plast Reconstr Surg.* 2009;123(2):627–34. <https://doi.org/10.1097/PRS.0b013e3181956664>
- Norholt SE, Jensen J, Schou S, Pedersen TK. Complications after mandibular distraction osteogenesis: a retrospective study of 131 patients. *Oral Surg Oral Med Oral Pathol Oral Radiol Endod.* 2011;111(4):420–7.
- Dunaway DJ, Britto JA, Abela C, Evans RD, Jeelani NUO. Complications of frontofacial advancement. *Child's Nervous System.* 2012;28:1571–6.
- Verlinden CR, van de Vijfeijken SE, Tuinzing DB, Becking AG, Swennen GRJ. Complications of mandibular distraction osteogenesis for acquired deformities: a systematic review of the literature. *Int J Oral Maxillofac Surg.* 2015;44(8):956–64.
- Troulis MJ, Kaban LB. Complications of mandibular distraction osteogenesis. *Oral Maxillofac Surg Clin North Am.* 2003;15(2):251–64.
- Master DL, Hanson PR, Gosain AK. Complications of mandibular distraction osteogenesis. *J Craniofac Surg.* 2010;21(5):1565–70.
- Hanson P. Treatment planning and orthodontic management of patients undergoing mandibular distraction osteogenesis. In: Samchukov ML, Cope JB, Cherkashin AM, editors. *Craniofacial Distraction Osteogenesis*. St. Louis: Mosby, Inc.; 2001. 156–166.
- Gateo I, Teichgraber I, Aguiar IT. Computer planning for distraction osteogenesis. *Plast Reconstr Surg.* 2000;105:873.
- Alwala AM, Kasireddy SK, Nalamolu B, Malyala SK. Transport distraction osteogenesis in reconstruction of condyle: use of a 3D model for vector planning. *J Maxillofac Oral Surg.* 2018;17(3):276–80.
- Stucki-McCormick SU, Clarizio LF. Complications associated with distraction osteogenesis. In: Gassner R, editor: *Complications in Cranio-maxillofacial and Oral Surgery*. Cham: Springer, 2020. https://doi.org/10.1007/978-3-030-40150-4_3
- Chen K, Xiao D, Abotaleb B, Chen H, Li Y, Zhu S. Accuracy of virtual surgical planning in treatment of temporomandibular joint ankylosis using distraction osteogenesis: comparison of planned and actual results. *J Oral Maxillofac Surg.* 2018;76(11):2422.e1–22.e20. <https://doi.org/10.1016/j.joms.2018.07.003>
- Yu H, Wang B, Wang M, Wang X, Shen SG. Computer-assisted distraction osteogenesis in the treatment of hemifacial microsomia. *J Craniofac Surg.* 2016;27(6):1539–42. <https://doi.org/10.1097/SCS.0000000000002838>
- Resnick CM. Virtual surgical planning for mandibular distraction in infants with Robin sequence. *Plast Reconstr Surg Glob Open.* 2017;5(6):e1379. <https://doi.org/10.1097/GOX.0000000000001379>
- Freitas RD, Tolazzi AR, Alonso N, Cruz GAO, Busato L. Evaluation of molar teeth and buds in patients submitted to mandible distraction: long-term results. *Plast Reconstr Surg.* 2008;121(4):1335–42.
- Wijbenga JG, Verlinden CR, Jansma J, Becking AG, Stegenga B. Long-lasting neurosensory disturbance following advancement of the retrognathic mandible: distraction osteogenesis versus bilateral sagittal split osteotomy. *Int J Oral Maxillofac Surg.* 2009;38(7):719–25.
- Mofid MM, Manson PN, Robertson BC, Tufaro AP, Elias JJ, Vander Kolk CA. Craniofacial distraction osteogenesis: a review of 3278 cases. *Plast Reconstr Surg.* 2001;108(5):1103–17.
- Uckan S, Veziroglu F, Arman A. Unexpected breakage of mandibular midline distraction device: case report. *Oral Surg Oral Med Oral Pathol Oral Radiol Endod.* 2006;102(6):e21–e25.
- Hurmerinta K, Peltomaki T, Hukki J. Unexpected events during mandibular distraction osteogenesis. *Scand J Plast Reconstr Surg Hand Surg.* 2004;38(4):209–14.
- Ahn J-G, Figueroa M, Braun S. Biomechanical considerations in distraction of the osteotomized dentomaxillary complex. *Am J Orthod Demofac Orthop.* 1999;116:264.
- Stuki-McCormick SU, Drew S, Mizrahi RD. Distraction osteogenesis: overcoming the challenges of a new technique. In: Samchukov ML, Cope JB, Cherkashin AM, editors: *Craniofacial Distraction Osteogenesis*. St. Louis: Mosby, Inc.; 2001:595–603.
- van Strijen PJ, Breuning KH, Becking AG. Stability after distraction osteogenesis to lengthen the mandible: results in 50 patients. *J Oral Maxillofac Surg.* 2004;62(3):304–7.
- van Strijen PJ. Complications in bilateral mandibular distraction osteogenesis using internal devices. *Oral Surg Oral Med Oral Pathol Oral Radiol Endod.* 2003;96:392–7.
- Schlund M, Touzet-Roumazelle S, Nicot R, Ferri J. Temporomandibular joint ankylosis following mandibular distraction osteogenesis: a dreadful complication. *J Craniofac Surg.* 2020;31(1):222–5. <https://doi.org/10.1097/SCS.0000000000005911>

How to cite this article: Kende PP, Sarda AS, Desai H, Landge J, Nimma V, Varte V. Complications of distraction osteogenesis: Narrative review. *Oral Surg.* 2021;00:1–11. <https://doi.org/10.1111/ors.12613>